

Korigirana Fallotova tetralogija u odrasloj dobi – prikaz slučaja i kratki pregled literature

Repaired Tetralogy of Fallot in Adults – Case Report and a Short Literature Review

Irena Ivanac Vranešić*,
Maja Strozzi

Medicinski fakultet Sveučilišta u Zagrebu, Klinički bolnički centar Zagreb, Zagreb, Hrvatska

University of Zagreb School of Medicine, University Hospital Centre Zagreb, Zagreb, Croatia

RECEIVED:
January 14, 2016

ACCEPTED:
January 30, 2016



SAŽETAK: Bolesnici s korigiranom Fallotovom tetralogijom (ToF), zbog razvoja mogućih komplikacija upravo u odrasloj dobi, trebaju se redovito kontrolirati u tercijarnom centru za prirodene bolesti srca (PBS) u odraslih. U slučaju stabilnog tijeka bolesti kontrole su najčešće indicirane u jednogodišnjem intervalu. Važno je, osim detaljne anamneze o eventualnoj pojavi simptoma, uvijek tražiti potencijalne komplikacije. Ako je riječ o značajnoj pulmonalnoj regurgitaciji (PR), što je najčešća kasna komplikacija korigirane ToF, potrebno ju je kvantificirati te pratiti promjenu u veličini i funkciji desne klijetke (DK). Važno je u donošenju odluke o reoperaciji na pulmonalnoj valvuli (PV) ne čekati predugo radi očuvanja funkcije DK, ali i imati u vidu bržu progresiju disfunkcije proteze ako se ugradi u mlađoj dobi. Budući da su ovakvi bolesnici u jednoj od najrizičnijih skupina unutar populacije odraslih s prirođenim bolestima srca za pojavu iznenadne srčane smrti, potrebno je njihov rizik stratificirati za sada dostupnim metodama i razmotriti postoji li indikacija za implantaciju kardioverter-defibrilatora. Osim navedenih, potrebno je pri svakoj kontroli tragati i za svim ostalim mogućim komplikacijama radi što boljeg i sveobuhvatnijeg praćenja i liječenja ovih bolesnika.

SUMMARY: Patients with repaired tetralogy of Fallot (ToF), due to the development of complications in adulthood, need to attend regular follow-up at a tertiary adult congenital heart disease (ACHD) center. If disease progression is stable, the follow-up visits are most often indicated on a yearly basis. In addition to a detailed history of symptoms development, it is important to always look for possible complications. In case of a significant pulmonary regurgitation (PR), which is the most frequent late complication of repaired ToF, it needs to be quantified, and changes in right ventricular (RV) size and function need to be monitored. It is important not to postpone the re-intervention on the pulmonary valve (PV) for too long in order to preserve the RV function. It is also important to bear in mind the possible faster progression of prosthesis dysfunction if the operation was done at an earlier age. Since repaired ToF patients belong to the group of ACHD conditions with the highest risk of sudden cardiac death (SCD), it is necessary to stratify their risk by using currently available methods and to consider whether there are any indications for the implantation of a cardioverter defibrillator. In addition to the above, during each follow-up it is necessary to search for all other possible complications in order to better and more comprehensively monitor and treat these patients.

KLJUČNE RIJEČI: Fallotova tetralogija, komplikacije, pulmonalna regurgitacija, ventrikulska tahikardija, prirodene bolesti srca u odraslih.

KEYWORDS: tetralogy of Fallot, complications, pulmonary regurgitation, ventricular tachycardia, adult congenital heart disease.

CITATION: *Cardiol Croat.* 2016;11(1-2):59–65. | DOI: <http://dx.doi.org/10.15836/ccar.2016.59>

*ADDRESS FOR CORRESPONDENCE: Irena Ivanac Vranešić, Klinički bolnički centar Zagreb, Kišpatićeva 12, HR-10000 Zagreb, Croatia. / Phone: +385-1-2388-888 / E-mail: irena.ivanac@gmail.com

ORCID: Irena Ivanac Vranešić, <http://orcid.org/0000-0002-6910-9720> • Maja Strozzi, <http://orcid.org/0000-0003-4596-8261>

Prikaz slučaja

Dvadesetogodišnja bolesnica elektivno je primljena radi dijagnostičke obrade. Riječ je o bolesnici kojoj je u drugoj godini života učinjena totalna korekcija Fallotove tetralogije (ToF) i koja se redovito kontrolirala kod pedijatrijskog kardiologa te je cijelo vrijeme bila bez simptoma. Na

Case report

A 23-year-old female was admitted for elective diagnostic follow-up. At the age of 2, the patient had undergone a total tetralogy of Fallot (ToF) repair and had been regularly attending follow-up visits by her pediatric cardiologist and was asymptomatic the entire time. During the latest

zadnjoj pedijatrijskoj kontroli ehokardiografski su opisane blaga rezidualna pulmonalna stenoza (PS) s maksimalnim sistoličkim gradijentom tlaka (PG) od 20 mmHg, blaga pulmonalna regurgitacija (PR), blago povećana desna klijetka (DK), minimalna trikuspidna regurgitacija (TR) i nije nađen rezidualni ventrikulski septalni defekt (VSD).

Na prvoj kontroli kod adultnog kardiologa ehokardiografski se i dalje opisivala blaga rezidualna PS s maksimalnim sistoličkim PG-om od 30 mmHg, a PR se nije spominjala (retrogradno je, detaljnijom analizom pohranjenih ehokardiografskih zapisa, utvrđeno da je postojala, no kako se poslije u tekstu ističe, ehokardiografska procjena PR-a izrazito je kompleksna te se lako može podcijeniti). Nađena je i hipertrofična te blago dilatirana DK (enddiastolička areja DK od 30 cm²) očuvane sistoličke funkcije (TAPSE 20 mm), kao i blaga TR. U 24-satnom kontinuiranom elektrokardiogramu nisu zabilježeni bitni poremećaji ritma. Nakon godinu dana bolesnica se javila na kontrolu kardiologu iz tima za PBS u odraslih. I dalje je bila bez simptoma, a u kliničkom je statusu nađen čujan sistolički šum 2 – 3/6 s punctum maximum nad pulmonalnim ušćem. U 12-kanalnom EKG-u ustanovljen je sinusni ritam frekvencije 83/min uz blok desne grane (duljina QRS-a 142 ms) i QTc od 454 ms. Na kontrolnom 24-h holteru EKG-a zabilježene su 2 epizode ventrikulske tahikardije (VT) frekvencije 150-180/min u trajanju od 10 sekundi, čije je ishodište, prema izgledu QRS-a, vjerojatno bilo u izgonskom traktu DK (RVOT). Tijekom ehokardiografske kontrole ustanovljena je dilatirana, volumno opterećena DK s diastoličkim pomakom septuma ulijevo (diastolička areja DK od 34,7 cm²), još očuvane sistoličke funkcije prema FAC-u koji je iznosio 50 % i TAPSE od 22 mm, ali ipak reduciranog s' na 7,6 m/s. Ustanovljena je značajna (vjerojatno teška) PR (slika 1 i slika 2; PHT od 87 ms, vrijeme bez protoka u diastoli iznosilo je 150 ms, bio je prisutan reverzni protok u PA, mlaz regurgitacije iznosio je 60 % RVOT-a, a VC 0,6 cm), dok je maksimalni sistolički PG preko pulmonalne valvule (PV) iznosio 20 mmHg. Nađena je blaga TR te maksimalni sistolički tlak u DK od 44 mmHg. Ascendentna aorta bila je granično uvećana na 3,7 cm, bez prisutne aortne regurgitacije, a lijeva je klijetka bila normalne veličine i funkcije i nije bio vidljivog VSD-a. S obzirom na nepostojanu VT u asimptomatske bolesnice, uvedena je peroralna terapija

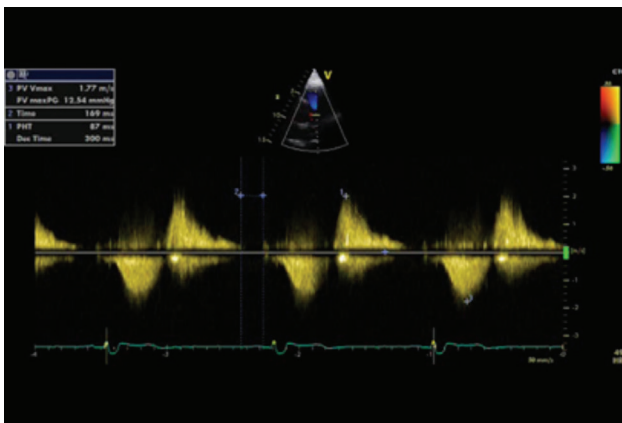


FIGURE 1. Continuous wave Doppler across the pulmonary valve showing severe pulmonary regurgitation.

pediatric follow-up, the echocardiogram reported a mild residual pulmonary valve stenosis (PS) with a maximal systolic pressure gradient (PG) of 20 mmHg, mild pulmonary regurgitation (PR), a mildly enlarged right ventricle (RV), minimal tricuspid regurgitation (TR) and no residual ventricular septal defect (VSD).

During the first follow-up by an adult cardiologist echocardiogram still showed a mild residual PS with a maximal systolic PG of 30 mmHg; PR was not mentioned (retroactively, through detailed analysis of the digitally stored echocardiogram, it has been established that PR existed, but as the later text emphasizes, echocardiographic assessment of PR is very complex and is easily underestimated). Also noted was the hypertrophic and mildly dilated RV (end-diastolic RV area of 30 cm²) with preserved systolic function (TAPSE 20 mm), as well as mild TR. During a 24-hour Holter ECG no significant rhythm disturbances were noted. After one year, the patient has come to a follow-up by a cardiologist from the adult congenital heart disease (ACHD) team. She was still asymptomatic, and among the clinical findings a systolic murmur 2-3/6 with punctum maximum above the pulmonary valve was observed. A sinus rhythm with a heart rate of 83/min, right bundle branch block (QRS length of 142 ms) and QTc duration of 454 ms was identified on the ECG. During the follow-up 24-hour Holter ECG, two episodes of ventricular tachycardia (VT) were noticed with a frequency of 150-180/min lasting 10 seconds whose source, judging by the appearance of the QRS, was most likely in the right ventricular outflow tract (RVOT). Echocardiographic follow-up indicated a dilated (diastolic RV area of 34.7 cm²), volume-overloaded RV with a diastolic septal shift to the left and still preserved RV systolic function according to FAC (fractional area change) of 50% and a tricuspid annular plane systolic excursion (TAPSE) of 22 mm, but with reduced s' to 7.6 m/s. A significant (probably severe) PR was noted (Figure 1 and Figure 2; PHT of 87 ms, time without flow during diastole was 150 ms, present PA reverse flow, regurgitation jet occupied 60% of the RVOT width, and VC was 0.6 cm) while the maximum systolic PG across the pulmonary valve (PV) was 20 mmHg. A mild TR and the maximal RV systolic pressure of 44 mmHg were noted. The ascending aorta was borderline enlarged to 3.7 cm, without the presence of aortic regurgitation, and the left ventricle (LV) was normal in size and function and no visible VSD was noticed. Considering the non-sustained VT in the asymptomatic patient, a therapy with sotalol was started in a dosage of 2x20 mg. Follow-up 24-hour Holter ECG after 6 days showed no ectopic ventricular activity. Cardiopulmonary exercise testing was performed as well, but it was stopped in the 6th minute because of maximal workload achieved with a satisfactory maximal oxygen uptake of 31 ml/kg/min, a normal increase in arterial pressure and pulse, and without the occurrence of arrhythmia. In the subsequent follow-up period cardiovascular magnetic resonance (CMR) imaging was conducted in another institution. CMR indicated the following: LV of normal size and preserved systolic function, no VSD, normal morphology of the large blood vessels, dilated and trabeculated RV (EDVI of 145 ml/m², ESVI of 69.1 ml/m²) with normal wall thickness and maintained global systolic function (ejection fraction of RV was 44%). CMR also showed a normal morphology of the PV with

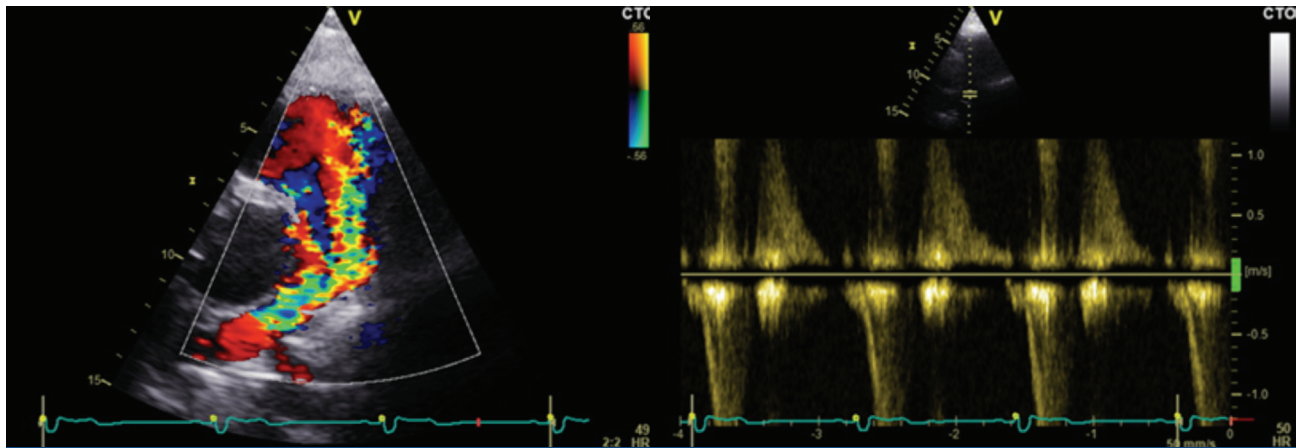


FIGURE 2. Color Doppler and pulsed wave Doppler with the sample volume in the pulmonary artery showing reversed flow in the pulmonary artery during diastole.

sotalolom u dozi od 2 x 40 mg. Kontrolni 24-satni holter EKG-a nakon 6 dana bio je bez ekotopične ventrikulske aktivnosti. Učinjena je i spiroergometrija koja je prekinuta u 6. minuti zbog postignutog maksimalnog opterećenja, uz zadovoljavajuću vršnu potrošnju kisika od 31 mL/kg/min te uredan porast arterijskoga tlaka i pulsa, kao i bez pojave aritmija.

U daljnjemu kontrolnom intervalu u vanjskoj ustanovi učinjena je i magnetna rezonancija (MR) srca u čijem nalazu je opisano sljedeće: normalno velika LK očuvane sistoličke funkcije, bez VSD-a, uredna morfologija velikih krvnih žila te dilatirana i trabekulirana DK (indeksirani teledijastolički volumen 145 mL/m², indeksirani telesistolički volumen 69,1 mL/m²), uredne debljine stijenke i održane globalne sistoličke funkcije (ejekcijska frakcija DK iznosila je 44 %). Opisana je također uredna morfologija PV s nešto ubrzanijim protokom, što je označeno kao PS srednjega stupnja te PR 2+. Nađena je dilatirana ascendentna aorta na razini Valsalvinih sinusa (4,0 cm), a na kasnoj imbibiciji gadolinijem opisana je punkti-formna zona imbibicije u srednjoj trećini prednje stijenke DK za koju se zaključilo da, s obzirom na dimenzije, ne bi trebala činiti aritmogeni supstrat. S obzirom na navedeno i, među ostalim, na procjenu veličine DK primjenom MR-a, za sada smo se odlučili za daljnje praćenje bolesnice i planiranje ponavljanja MR-a srca u kontrolnom periodu radi bolje definicije težine PR te praćenja eventualne progresije dilatacije i disfunkcije DK, kao i bolje evaluacije ostalih struktura. Odlučili smo se prikazati ovaj slučaj jer je to tipičan primjer bolesnika s korigiranom ToF koji u odrasloj dobi mogu razviti brojne probleme, o čemu će biti više riječi u nastavku teksta.

U ove je bolesnice ostalo nekoliko otvorenih pitanja koja će zahtijevati odgovor tijekom daljnjega praćenja. Neka su od njih preciznija kvantifikacija PR, određivanje pravoga vremena za operativni zahvat na PV, pitanje postojanja eventualne periferne stenozе plućne arterije, pitanje daljnje dijagnostike i liječenja VT (da li ostati na antiaritmiku, učiniti elektrofiziološku studiju ili samo pratiti, utvrditi postoji li indikacija za kardioverter-defibrilator) i dr. Ono što se ovim slučajem htjelo naglasiti jest potreba za boljom edukacijom svih kardiologa, kako adultnih, tako i pedijatrijskih, ali i radiologa (prije svega onih koji se bave MR-om) o specifičnostima odraslih bolesnika s prirodnim srčanim greškama jer će ih u svakodnevnoj

a slightly accelerated flow across the valve which was marked as moderate PS. A PR of grade 2+ was found as well. The examination showed a dilated ascending aorta at the aortic root level of 4.0 cm, and LGE showed a punctiform area of imbibition in the middle third of the RV anterior wall, which was concluded not to represent an arrhythmogenic substrate considering its dimensions. Bearing in mind all the above and especially the RV size estimated by CMR, for now we have decided to monitor the patient and to repeat the CMR in the follow-up period to better assess the severity of PR and possible progression of the RV dilation and dysfunction, and to better evaluate all other cardiovascular structures. We have decided to present this case because it is an example of a typical patient with a repaired ToF and problems that can occur in adulthood, which will be addressed in the section below.

Several questions were left unanswered in this case and will require an answer during further follow up. They include a more precise quantification of PR, determination of optimal timing for PV surgery, the question of possible peripheral pulmonary artery stenosis, the question of further diagnostics and treatment of VT (whether we should continue with the antiarrhythmic therapy, conduct an electrophysiological study, or just monitor and determine whether there are indications for a cardioverter defibrillator), and others. What we wanted to emphasize with this case report is the need for better education of all cardiologists, both adult and pediatric specialists as well as radiologists (primarily those who perform CMR), about the specificities of adult patients with congenital heart diseases (CHD) as those will be ever more numerous in everyday cardiology practice. Finally, these patients should be referred to tertiary ACHD centers where they will be monitored and treated by a team consisting of cardiologists, cardiac surgeons, radiologists, and other specialists dedicated to this group of patients.

Literature review

Tetralogy of Fallot is the most common cyanotic CHD¹. The incidence is around 10% of all CHD, and the rate of survival to adulthood is greater than 85%. In addition to VSD, overriding aorta, PV/RVOT stenosis (with possible PA stenosis at the le-

kardiološkoj praksi biti sve više. U konačnici je ipak te bolesnike potrebno usmjeriti u tercijarne centre za PBS odraslih, gdje će ih dalje pratiti i liječiti tim sastavljen od kardiologa, kardijalnih kirurga, radiologa i specijalista drugih grana medicine usko posvećenih ovoj skupini bolesnika.

Pregled literature

Fallotova tetralogija najčešća je cijanotična PBS¹. Incidencija iznosi oko 10 % svih PBS-a, a preživljenje u odraslu dob iznosi više od 85 %. Uz VSD, jašuću aortu, stenozu PV/RVOT-a (uz eventualne stenozu PA na razini debla, bifurkacije ili ogranka) i posljedičnu hipertrofiju DK mogu biti prisutne i dodatne anomalije u građi srca i velikih krvnih žila kao što su atrijski septalni defekt, perzistentni foramen ovale, desni luk aorte (u 25% slučajeva), anomalije koronarnih arterija (u 5% slučajeva), perzistentni duktus arteriozus i dr. Stoga je jako važno u svakog bolesnika s ToF-om sustavno tragati i za ostalim popratnim greškama. Mnogi su od takvih bolesnika u djetinjstvu prije totalne korekcije ToF-a zahtijevali neku od palijativnih operacija stvaranja sistemsko-pulmonalnog šanta radi povećanja protoka u plućnoj cirkulaciji, što je važno znati pri evaluaciji odraslog bolesnika. Totalna korekcija uključuje zatvaranje VSD-a zakrpom te rješavanje opstrukcije RVOT-a resekcijom infundibuluma i pulmonalnom valvulotomijom. Brojni bolesnici zahtijevaju još i RVOT ili transannularnu zakrpu, što se smatra jednim od glavnih uzroka postoperativne PR koja je jedan od glavnih problema odraslih bolesnika s korigiranom ToF. Od ostalih komplikacija koje se mogu pojaviti u odrasloj dobi mogu se naći rezidualna RVOT opstrukcija, dilatacija i disfunkcija DK, rezidualni VSD na mjestu zakrpe, dilatacija korijena aorte s posljedičnom aortnom regurgitacijom (AR), disfunkcija LK, atrijske i ventrikulske aritmije, iznenadna srčana smrt (SCD) te endokarditis koji se rijetko pojavljuje. Zbog svih navedenih problema koji zahtijevaju pomno praćenje, dodatnu dijagnostičku obradu i pravodobnu terapijsku intervenciju ove je bolesnike potrebno redovito kontrolirati u tercijarnom centru za PBS kako bi im se pružila optimalna medicinska skrb.

Pulmonalna regurgitacija jedan je od najčešćih problema ToF-a u odrasloj dobi i vrlo često je klinički značajna (bilo da je umjerena ili teška) te zahtijeva reoperaciju. Posljedica je korektivnog operativnog zahvata učinjenog u djetinjstvu, a on podrazumijeva pulmonalnu valvulotomiju te transannularnu inciziju i zakrpu. Adultni kardiolozi koji nisu dovoljno upoznati s problemima bolesnika s ToF-om ehokardiografski često previde PR jer je patologija PV u kardiologiji odraslih vrlo rijetko zastupljena, a i prikaz PV nije uvijek optimalan. Dodatni razlog neprepoznavanja veličine problema kod uočene PR jest i još uvijek nedovoljno definirana ehokardiografska procjena težine PR.

Prema posljednjim preporukama² Europskog udruženja za kardiovaskularno oslikavanje, težina PR-a uglavnom se procjenjuje kvalitativnim metodama, pri čemu na tešku PR upućuju parametri kao što je gusti doplerski signal regurgitacije na kontinuiranom Doppleru, reverzni tok u PA, skraćeni PHT (< 100 ms), rani prekid regurgitacijskog mlaza zbog brzog izjednačavanja tlakova u PA i DK (vrijeme bez protoka u diastoli > 80 ms) te neki semikvantitativni poput širine regurgitirajućeg mlaza u RVOT-u (> 65 %) ili VC koji još nisu dovoljno validirani.

vel of the trunk, bifurcation or distal branches) and resulting RV hypertrophy, additional anomalies in the structure of the heart and large blood vessels can be present, like atrial septal defect, persistent foramen ovale, right-sided aortic arch (in 25% of the cases), anomalies of the coronary arteries (in 5% of the cases), persistent ductus arteriosus, and others. This is why it is important to look for any other accompanying defects in all patients with ToF. During childhood and before total repair, many of these patients required palliative surgery creating a systemic-pulmonary shunt in order to increase the flow in the pulmonary circulation, which is important to note during the evaluation of the adult patient. Total repair includes VSD closure and relief of RVOT obstruction with resection of the infundibulum and pulmonary valvotomy. Many patients require an additional RVOT or transannular patch, which is considered one of the main causes of postoperative PR and which is one of the main problems in adults with repaired ToF. Other possible complications that can occur in adulthood are residual RVOT obstruction, RV dilation and dysfunction, residual VSD at patch location, dilation of the aortic root with the resulting aortic regurgitation (AR), dysfunction of the LV, atrial and ventricular arrhythmias, sudden cardiac death (SCD) and endocarditis, which occurs rarely. Because of all these potential issues which all require close monitoring, further diagnostics and timely treatment, these patients should attend regular follow-up at a tertiary ACHD center in order to receive optimal medical care.

Pulmonary regurgitation is one of the most frequent problems in adult patients after ToF repair and is often clinically significant (whether it is moderate or severe), and requires reoperation. It is the consequence of the previous surgery performed in childhood, which includes pulmonary valvotomy and transannular incision and patch. Adult cardiologists, who are not sufficiently familiar with the problems of patients with ToF, can often overlook PR during echocardiographic imaging because the incidence of PV pathology in general adult population is low, and the optimal imaging of PV is not always possible. An additional reason for misinterpretation of PR severity could be still insufficiently defined echocardiographic assessment of the PR severity.

According to the latest recommendations² of the European Association for Cardiovascular Imaging, the severity of PR is usually estimated through qualitative methods where severe PR is indicated by parameters such as dense Doppler signal of regurgitation jet with continuous wave Doppler imaging, presence of reversed flow in PA, short PHT (<100 ms) and early interruption of the regurgitation jet due to fast equalization of PA and RV diastolic pressures (time without diastolic flow >80 ms), and other semi-quantitative parameters such as the regurgitation jet with in RVOT (>65%) or VC, which have not yet been sufficiently validated. Quantitative parameters such as regurgitation volume, regurgitation fraction, and effective regurgitant orifice area (EROA) have also not been validated. However, the first indicators of severe PR could be the signs of RV volume overload (dilated RV and diastolic leftward shift of the interventricular septum). An assessment of the RV size and function is therefore necessary for every patient with PR, using all available echocardiographic methods and parameters usually used in adult cardiology (FAC, TAPSE, TDI s', and

Kvantitavni parametri poput regurgitirajućeg volumena, regurgitirajuće frakcije i efektivne regurgitirajuće areje (EROA) također nisu validirani. Međutim, ono što nas prvo može uputiti na značajnu PR jesu njezini učinci na DK, odnosno znakovi volumnog opterećenja DK (dilatirana DK i pomak septuma u dijastoli ulijevo). U svakog bolesnika koji ima značajnu PR potrebna je procjena veličine i funkcije DK svim dostupnim ehokardiografskim metodama i parametrima kojima se i inače koristimo u adultnoj kardiologiji (FAC, TAPSE, TDI s' i dr.). Longitudinalni 2D „strain“ u takvih je bolesnika reduciran i korelira s dilatacijom DK i težinom PR. Težina regurgitacije i jačina utjecaja na DK povećava se istodobnim postojanjem distalnih stenoza PA ili pak postojanjem plućne arterijske hipertenzije. S obzirom na reducirane ehokardiografske mogućnosti precizne kvantifikacije težine PR, potrebno je integrirati sve navedene parametre radi dobivanja što potpunijeg uvida u stvarnu težinu PR. Oslikavanje s pomoću MR-a srca jest „zlatni standard“ u procjeni stupnja PR-a, kao i veličine i funkcije DK. U procjeni težine PR-a najpouzdaniji je parametar regurgitirajuća frakcija (RF > 40 % = teška PR). Veličina (indeksirani enddijastolički volumen > 170 mL/m² i indeksirani endsistolčki volumen > 85 mL/m² nose lošu prognozu) i funkcija DK (EF), kao i njihova promjena tijekom praćenja ključni su parametri u procjeni trenutka reoperacije PV-a. Osim navedenog, MR je izvrsna metoda u procjeni veličine i funkcije LK, anatomije koronarnih arterija, aneurizmi RVOT-a, u dijagnostici stenoza PA i njenih ogranaka, procjeni ožiljno promijenjenog miokarda s kasnom imbibicijom gadolinijem, u izračunu šanta i dr. Značajna PR godinama se dobro podnosi, ali nakon prosječno 20-ak godina dovodi do dilatacije i disfunkcije DK te pojave simptoma srčanog popuštanja i aritmija, prije svega fibrilacije i undulacije atrija te VT-a. Prvi simptom u ovakvih bolesnika čak može biti i SCD pa se PR smatra jednim od glavnih čimbenika rizika za SCD u bolesnika s korigiranom ToF. Također je poznato da od svih odraslih bolesnika s PBS, bolesnici s ToF-om imaju najveći rizik za razvoj srčanog popuštanja. Liječenje PR sastoji se u zamjeni pulmonalnog zalistka (PVR), ali je pitanje optimalnoga trenutka u kojem to treba učiniti još uvijek bez jasnog odgovora. Prema smjernicama¹ Europskoga kardiološkog društva (ESC), smatra se da je važnija progresija u veličini ili disfunkciji DK nego apsolutna veličina navedenih parametara. Značajna dilatacija DK na MR-u srca (indeksirani teledijastolički volumen > 160 (170) mL/m² ili indeksirani telesistolčki volumen > 85 mL/m²) povezana je sa značajnom dilatacijom DK nakon PVR-a i lošijom prognozom³. Međutim, operacija u mlađoj dobi donosi brže propadanje biološke PV te raniju novu reoperaciju, odnosno reintervenciju. Kirurška zamjena zalistka u većini slučajeva čini se biološkom protezom ili homograftom. Perioperativni je mortalitet nizak (oko 1 %) u bolesnika bez uznapredovale disfunkcije klijetke i bez znakova srčanog popuštanja, a desetogodišnje preživljenje iznosi 92 – 95 %. U odraslih je bolesnika nova reoperacija potrebna nakon prosječno 10 – 15 god. Osim klasičnoga kirurškog zahvata, danas se primjenjuje i perkutana implantacija tzv. Melody valvule koja može biti indicirana u dijela bolesnika s PR i korigiranom ToF. Prema smjernicama¹ ESC-a, indikacija za zamjenu PV jest simptomatska teška PR, odnosno asimptomatska teška PR ako je prisutan jedan od sljedećih kriterija: pad u funkcijskom kapacitetu, progresivna TR, progresivna dilatacija ili disfunkcija DK, opstrukcija RVOT-a sa sistoličkim

others). In these patients, longitudinal 2D strain is reduced and correlates with RV dilation and the PR severity. The severity of the regurgitation and its effect on the RV are increased with the simultaneous presence of distal PA stenosis or the existence of pulmonary arterial hypertension. Considering the reduced echocardiographic capabilities of precise quantification of the PR severity, it is necessary to integrate all these parameters in order to achieve an insight into the real severity of PR as much as possible. CMR imaging is the gold standard for the assessment of the PR severity as well as for the RV size and function. The most reliable parameter for the assessment of PR is the regurgitation fraction (RF >40% = severe PR). The RV size (end-diastolic volume index >170 ml/m² and end-systolic volume index >85 ml/m² indicate a worse prognosis) and function (EF) as well as their change during the follow-up are crucial parameters in the assessment of the appropriate timing for repeated surgical intervention on PV. In addition to the above, CMR is an excellent method for the assessment of LV size and function, the anatomy of the great vessels, RVOT aneurisms, PA and branch stenosis, the assessment of the myocardial scar burden on LGE, for the shunt calculations, etc. Significant PR can be well tolerated for a long time, but after on average 20 years it leads to RV dilation and dysfunction and to the appearance of symptoms of heart failure and arrhythmias, primarily atrial fibrillation, atrial flutter and VT. Initial symptom in these patients can even be SCD, so PR is considered one of the main risk factors for SCD in patients with repaired ToF. It is also known that of all the patients with ACHD, patients with ToF have the greatest risk of developing heart failure. The treatment of PR consists of pulmonary valve replacement (PVR), but the question of the optimal timing for reoperation is still unanswered. According to the guidelines¹ of the European Society of Cardiology (ESC) the progression of RV dilation or dysfunction is considered more important than the absolute values of the stated parameters. Significant RV dilation on CMR (end-diastolic volume index >160 (170) ml/m² or end-systolic volume index >85 ml/m²) is associated with persistent RV dilation following PVR and a worse prognosis³. However, surgical procedures at an early age lead to more rapid deterioration of tissue PV and an earlier reoperation or reintervention. Surgical valve replacement is done in most cases with a tissue prosthesis or a homograft. Perioperative mortality is low (around 1%) in patients without advanced ventricular dysfunction or signs of heart failure, and the 10-year survival rate is 92-95%. In adult patients, a second reoperation is needed after 10-15 years on average. In addition to classical surgical procedures, there is also a possibility of percutaneous implantation of the so called "Melody" valve which can be indicated for some patients with PR and a repaired ToF. According to ESC guidelines¹, indication for the PV replacement is a severe symptomatic PR or severe asymptomatic PR if any of the following criteria is present: decrease in objective exercise capacity, progressive TR, progressive RV dilation or dysfunction, RVOT obstruction with systolic RV pressure of >80 mmHg (TR velocity >4.3 m/s) or the presence of sustained atrial or ventricular arrhythmias. Following PVR, regardless of the method, the functional capacity increases and RV decreases in size, but the long-term prognosis and the effect on the survival rate is still unknown.

tlakom u DK > 80 mmHg (brzina TR > 4,3 m/s) te prisutnost postojane atrijske, odnosno ventrikulske aritmije. Nakon PVR-a, neovisno o metodi, dolazi do porasta funkcijskog kapaciteta i smanjenja veličine DK, ali je pitanje dugoročne prognoze i utjecaja na preživljenje još uvijek nepoznato.

Rezidualna opstrukcija RVOT-a može biti na razini infundibuluma, PV-a, PA, bifurkacije, u ograncima lijeve i desne PA (često posljedica prethodnih palijativnih operacija) te na anastomozama provodnika. Ona pogoršava funkciju DK i povećava PR u slučaju distalnih stenoza. S obzirom na to da je često nemoguće precizno izmjeriti maksimalni gradijent u RVOT-u, najpreciznija ehokardiografska procjena tlaka u DK je pomoću prikaza mlaza TR primjenom kontinuiranog doplera. Terapija je kirurško rješavanje opstrukcije ili perkutana dilatacija (u slučaju stenozе perifernih ogranaka). Operativni zahvat zamjene PV indiciran je u slučaju simptomatske teške PS (sistolčki tlak u DK > 60 mmHg, brzina iz TR > 3,5 m/s), odnosno u slučaju asimptomatske PS ako je prisutan i jedan od sljedećih kriterija: pad u funkcijskom kapacitetu, progresivna TR, progresivna dilatacija ili disfunkcija DK, opstrukcija RVOT-a sa sistoličkim tlakom u DK > 80 mmHg (brzina TR > 4,3 m/s) te prisutnost postojane atrijske, odnosno ventrikulske aritmije.

Dilatacija i disfunkcija DK može biti uzrokovana, kako je već opisano, dugotrajnom značajnom PR i opstrukcijom RVOT-a zbog volumnog, odnosno tlačnog opterećenja, ali je često dijelom i posljedica prisutnosti postoperativnih ožiljaka. Jedan od uzroka disfunkcije DK može biti i disinkronija zbog prisutnog bloka desne grane pa u nekih bolesnika može biti indicirana i resinkronizacijska terapija. Posljedica dilatacije DK često je značajna TR koja onda vodi u začarani krug daljnje dilatacije i pogoršanja funkcije DK, a to u konačnici vodi razvoju srčanog popuštanja, povećanom riziku od aritmija i SCD.

Jedan od mogućih problema odraslih bolesnika nakon korigirane ToF može biti i rezidualni VSD zbog dehiscencije zakrpe. Najčešće je mali s restriktivnim šantom (visoki gradijent), ali, ako je znatan ($Q_p : Q_s = 1,5 : 1$), tada dovodi do volumnog opterećenja LK i razvoja plućne hipertenzije te ga je potrebno kirurški korigirati. Indikacija za zatvaranje VSD-a prisutna je i ako se planira operacija na PV.

Smatra se da su uzroci disfunkcije LK u ovakvih bolesnika višestruki. Najčešće se u literaturi spominju dugotrajna cijanoza prije operacije, volumno opterećenje zbog dugotrajnih palijativnih arterijskih šantova, rezidualnog VSD-a ili AR-a, postojanje koronarne bolesti srca, interventrikulska interakcija u slučaju teške PR i dr. Ovaj se problem pojavljuje u kasnijoj fazi bolesti i važan je prognostički čimbenik za SCD i loš klinički ishod.

Uzrok dilatacije korijena aorte nije potpuno jasan. Može dovesti do razvoja AR-a, a progresivna se dilatacija viđa se u 15 % odraslih bolesnika nakon korekcije ToF-a. Smatra se da je uzrokovana intrinzičnom bolešću aorte, kao i povećanim protokom kroz aortu (npr. kod pulmonalne atrezije) te kasnom korekcijom greške. Veličina je aorte uglavnom manja od 5 cm i rijetko dovodi do disekcije, a češće je prisutna u muških bolesnika. Indikacija za zamjenu aortne valvule prisutna je ako postoji teška simptomatska AR, odnosno asimptomatska teška AR uz znakove disfunkcije LK.

Residual RVOT obstruction can occur at the level of the infundibulum, PV, PA, bifurcation, in the branches of left or right PA (often the result of the previous palliative surgery), and at the conduit anastomoses sites. It impairs the RV function and increases PR in the case of co-existent distal stenosis. Considering the fact that it is often impossible to precisely measure the maximum gradient in RVOT, the most precise echocardiographic assessment of the RV pressure is from the TR velocity acquired from a continuous-wave Doppler imaging. The therapy is a surgical relief of the obstruction or the percutaneous dilation (for example, in the case of the peripheral branch stenosis). Surgical PVR is indicated in cases of severe symptomatic PS (RV systolic pressure >60 mmHg, TR velocity >3.5 m/s) or in case of asymptomatic PS if any of the following criteria are present: decrease in objective exercise capacity, progressive TR, progressive RV dilation or dysfunction, RVOT obstruction with RV systolic pressure >80 mmHg (TR velocity >4.3 m/s) or the presence of a sustained atrial or ventricular arrhythmias.

RV dilation and dysfunction can be caused, as described before, by long-term severe PR and/or RVOT obstruction due to the volume or pressure overload but it is also often partly caused by the presence of postoperative myocardial scar formation. One of the causes of RV dysfunction can be dyssynchrony due to the presence of a RBBB, thus for some patients resynchronization therapy (CRT) can be indicated. The consequence of the RV dilation is often significant TR which leads into a vicious cycle of further dilation and deterioration of RV function, and this eventually leads to the development of heart failure and to an increased risk of arrhythmias and SCD.

One of the possible problems for adult patients after the repair of ToF can also be a residual VSD due to the patch dehiscence. Most often VSD is small with restrictive flow (high pressure gradient), but if it is significant ($Q_p:Q_s = 1.5:1$) then it leads to LV volume overload and development of pulmonary hypertension, and needs to be surgically corrected. VSD closure is also indicated if PV surgery is planned.

It is believed that there are multiple causes of LV dysfunction in these patients. Most often mentioned in the literature are long-term cyanosis prior to the operation, volume overload due to long-term palliative arterial shunts, residual VSD or AR, the presence of coronary heart disease, interventricular dependence in the case of severe PR, and others. This problem appears at a later phase of the illness and is a significant prognostic factor for SCD and an adverse clinical outcome.

The cause of the aortic root dilation is still not completely clear. It can lead to the development of AR, and a progressive dilation is seen in 15% of the adult patients after repaired ToF. It is believed to be caused by the intrinsic disease of the aorta, as well as by the increased aortic flow (for example in the case of pulmonary atresia) and late repair of the defect. The size of the aorta is usually less than 5 cm and rarely leads to dissection, and is more often present in male patients. Aortic valve replacement is indicated if there is a severe symptomatic AR, or severe asymptomatic AR with the signs of LV dysfunction.

Arrhythmias and SCD are one of the most frequent problems in this group of patients. Atrial fibrillation/flutter and

Aritmije i SCD jedan su od najčešćih problema ove skupine bolesnika. Fibrilacija/undulacija atrijske i ventrikulske tahikardije mogu biti posljedica progresivnih hemodinamskih problema i/ili stvaranja ožiljka nakon operativnog zahvata u području RVOT-a i VSD-a. ToF je jedna od PSG s najvišim rizikom za SCD, koji iznosi oko 2% u desetogodišnjem intervalu i uzrokuje trećinu do polovicu svih kasnih smrti u ovoj populaciji. Poznati su neki čimbenici rizika za pojavu SCD kao što su trajanje QRS-a > 180 ms, volumno opterećenje DK, disfunkcija LK i DK, proširena fibroza klijetke na MR srca, dugotrajni paliativni šantovi, nepostojana VT u 24-satnom holteru EKG-a te klinička i inducibilna postojana VT. Bolesnici sa simptomima (sinkopom, vrtoglavicom, palpitacijama) trebaju detaljnu hemodinamsku i elektrofiziološku evaluaciju. U asimptomatskih bolesnika s nepostojanom VT potreban je individualan pristup ovisno o ostalim kliničkim obilježjima (čimbenicima rizika za SCD). Budući da nema jasnih podataka, pristup liječenju ovakvih bolesnika varira od isključivoga praćenja, preko antiaritmijske terapije do elektrofiziološke studije/ablacije i ugradnje kardioverterskog defibrilatora (ICD). Primjena ICD-a svakako je indicirana u sekundarnoj prevenciji SCD (postojana VT, stanje nakon aresta), ali je stratifikacija rizika u primarnoj prevenciji SCD vrlo teška i za sada nema potpuno jasnih smjernica, iako postoje neki prijedlozi pojedinih autora⁴. Pri donošenju odluke o eventualnoj ugradnji ICD-a, ovim uglavnom mladim osobama, svakako treba uzeti u obzir i poznate potencijalne komplikacije koje se mogu pojaviti nakon ugradnje kao što su endokarditis ili neadekvatna uključivanja uređaja i sl. Prema posljednjim smjernicama⁵ ESC-a, ugradnju ICD-a treba razmotriti u odabranih bolesnika s ToF-om i višestrukim čimbenicima rizika za SCD, uključujući disfunkciju LK, nepostojanu VT, QRS dulji od 180 ms ili inducibilnu postojanu VT na elektrofiziološkom testiranju. Elektrofiziološko testiranje može se razmotriti u stratifikaciji rizika za naglu srčanu smrt u bolesnika s ToF-om koji imaju jedan ili više čimbenika rizika kao što su disfunkcija LK, nepostojana VT i QRS dulji od 180 ms.

ventricular tachycardia can be the consequence of the progressive hemodynamic problems and/or scar formation after the RVOT operation and VSD closure. ToF is one of the ACHD with the greatest risk of SCD of around 2% in the 10-year interval and causes between one third and one half of all late deaths in this population. Some risk factors for SCD are known, such as QRS >180 ms, RV volume overload, LV and RV dysfunction, large areas of ventricular fibrosis on CMR, long-term palliative shunts, VT in the 24-hour Holter ECG, and the clinical and inducible sustained VT. Patients with symptoms (syncope, dizziness, palpitations) require a detailed hemodynamic and electrophysiological evaluation. Asymptomatic patients with non-sustained VT require an individual approach dependent on other clinical characteristics (SCD risk factors). Since there is no clear data, the treatment approach for these patients varies from purely monitoring to antiarrhythmic therapy, electrophysiological study/ablation and implantation of a cardioverter defibrillator (ICD). ICD implantation is definitely indicated in secondary prevention of SCD (sustained VT and after cardiac arrest), but risk stratification in primary SCD prevention is very difficult and there are currently no clear guidelines although there are some suggestions from certain authors⁴. While considering the possible implantation of ICD in these usually young persons, one should bear in mind the known possible complications that can occur after the implantation, such as endocarditis or inappropriate device activation and similar complications. According to the latest ESC guidelines⁵, ICD implantation should be considered for patients with ToF and multiple SCD risk factors, which include LV dysfunction, non-sustained VT, QRS duration longer than 180 ms, or inducible sustained VT during electrophysiological study. Electrophysiological study can be considered for the SCD risk stratification in patients with ToF who have one or more risk factors such as LV dysfunction, non-sustained VT, and QRS duration longer than 180 ms.

LITERATURE

- Baumgartner H, Bonhoeffer P, De Groot NM, de Haan F, Deanfield JE, Galie N, et al; Task Force on the Management of Grown-up Congenital Heart Disease of the European Society of Cardiology (ESC); Association for European Paediatric Cardiology (AEPC); ESC Committee for Practice Guidelines (CPG). ESC Guidelines for the management of grown-up congenital heart disease (new version 2010). *Eur Heart J*. 2010;31(23):2915-57. DOI: <http://dx.doi.org/10.1093/eurheartj/ehq249>
- Lancellotti P, Tribouilloy C, Hagendorff A, Moura L, Popescu BA, Agricola E, et al; European Association of Echocardiography. European Association of Echocardiography recommendations for the assessment of valvular regurgitation. Part I: aortic and pulmonary regurgitation (native valve disease). *Eur J Echocardiogr*. 2010;11(3):223-44. DOI: <http://dx.doi.org/10.1093/ejechocard/jeq030>
- Therrien J, Provost Y, Merchant N, Williams W, Colman J, Webb G. Optimal timing for pulmonary valve replacement in adults after tetralogy of Fallot repair. *Am J Cardiol*. 2005;95(6):779-82. DOI: <http://dx.doi.org/10.1016/j.amjcard.2004.11.037>
- Khairy P, Harris L, Landzberg MJ, Viswanathan S, Barlow A, Gatzoulis MA, et al. Implantable cardioverter-defibrillators in tetralogy of Fallot. *Circulation*. 2008;117:363-70. DOI: <http://dx.doi.org/10.1161/CIRCULATIONAHA.107.726372>
- Priori SG, Blomström-Lundqvist C, Mazzanti A, Blom N, Borggrefe M, Camm J, et al; Authors/Task Force Members; Document Reviewers. 2015 ESC Guidelines for the management of patients with ventricular arrhythmias and the prevention of sudden cardiac death: The Task Force for the Management of Patients with Ventricular Arrhythmias and the Prevention of Sudden Cardiac Death of the European Society of Cardiology (ESC) Endorsed by: Association for European Paediatric and Congenital Cardiology (AEPC). *Eur Heart J*. 2015;36(41):2793-867. DOI: <http://dx.doi.org/10.1093/eurheartj/ehv316>