



# Aritmogeni kardiomiopatija desne klijetke

## Arrhythmogenic right ventricular cardiomyopathy

 Juraj Jug<sup>1</sup>,

 Martina Lovrić Benčić<sup>2\*</sup>

<sup>1</sup>Sveučilište u Zagrebu, Medicinski fakultet, Zagreb, Hrvatska

<sup>2</sup>Medicinski fakultet Sveučilišta u Zagrebu, Klinički bolnički centar Zagreb, Zagreb, Hrvatska

<sup>1</sup>University of Zagreb, School of Medicine, Zagreb, Croatia

<sup>2</sup>University of Zagreb School of Medicine, University Hospital Centre Zagreb, Zagreb, Croatia

RECEIVED:  
February 14, 2019

UPDATED:  
February 22, 2019

ACCEPTED:  
February 28, 2019



**SAŽETAK:** Aritmogeni kardiomiopatija desne klijetke (ARVC) rijetka je progresivna autosomno-dominantna genska bolest karakterizirana strukturnim nepravilnostima desne klijetke te pojavom aritmija mehanizma kruženja. Unutar više od 140 različitih mutacija gena najznačajnije su one za proteine interkaliranih diskova te dezmosoma miokarda. Degeneracija i smrt miocita, koje nastaju zbog poremećena rasta i diferencijacije miocita, najočitiije su u području trokuta displazije, a očituju se vrlo nespecifičnim simptomima. Aritmije nastale zbog ARVC-a smatraju se glavnim uzrokom smrti u osoba mlađih od 40 godina. Budući da postoje brojne druge bolesti koje nalikuju na ARVC, njegova se dijagnoza postavlja na temelju kombinacije zadovoljavanja uvjeta kriterija radne skupine te nalaza magnetne rezonancije, biopsije srca i ehokardiografije. Unatoč svim dijagnostičkim kriterijima, više od 50 % pravih ARVC-a i dalje ostaje neadekvatno dijagnosticirano. Upravo zbog te činjenice asimptomatskim sportašima s pozitivnom obiteljskom anamnezom savjetuje se detaljno i učestalo praćenje zdravstvenoga stanja od rane životne dobi. Glavni cilj liječenja ARVC-a jest prevencija iznenadne srčane smrti. U medikamentnoj terapiji prednost se i dalje daje sotalolu te amiodaronu u svrhu prevencije razvoja malignih aritmija. Uz vrlo visok rizik od nastanka takvih aritmija bolesnicima je u primarnoj prevenciji apsolutno indicirana ugradnja kardioverterskih defibrilatora. Uspješnost radiofrekventne ablacije u ovoj bolesti niža je zbog učestale pojave novih žarišta aritmije uzrokovanih masno fibroznom promjenama miokarda te se smatra palijativnom metodom liječenja. Definitivno izlječenje ove bolesti može se postići isključivo transplantacijom srca.

**SUMMARY:** Arrhythmogenic right ventricular cardiomyopathy (ARVC) is a rare progressive autosomal dominant genetic disease characterized by structural abnormalities of the right ventricle of the heart and the appearance of the reentry type arrhythmias. Of the 140 different genetic mutations, the most significant are those related to proteins in the intercalated discs and myocardial desmosomes. Myocyte degeneration and death, which are caused by disrupted myocyte growth and differentiation, are most obvious in the triangle of dysplasia and result in very non-specific symptoms. Arrhythmias caused by ARVC are considered the main cause of death in persons below 40 years of age. Since there are numerous other diseases that resemble ARVC, the diagnosis of ARVC is established based on a combination of fulfilling the working group criteria and magnetic resonance imaging, heart biopsy, and echocardiography findings. Despite all the diagnostic criteria, more than 50% of real ARVC cases remain inadequately diagnosed. This is why detailed and frequent health checkups from an early age are recommended in asymptomatic athletes with family history positive for ARVC. The main goal of treatment is the prevention of sudden cardiac death. Sotalol and amiodarone are favored in medication therapy, with the goal of preventing the development of malignant arrhythmias. In patients with a very high risk of such arrhythmias the implantation of a cardioverter defibrillator is absolutely indicated as part of primary prevention. The successfulness of radiofrequency ablation is lower in this disease due to the frequent appearance of new arrhythmic foci caused by fatty fibrotic changes in the myocardium and is considered a palliative treatment method. Definitive treatment for this diseases can be achieved only through heart transplantation.

**KLJUČNE RIJEČI:** aritmogeni kardiomiopatija desne klijetke, zatajivanje srca, iznenadna srčana smrt, ventrikulske ekstrasistole.

**KEYWORDS:** arrhythmogenic right ventricular cardiomyopathy, heart failure, sudden cardiac death, ventricular extrasystoles.

**CITATION:** *Cardiol Croat.* 2019;14(1-2):12-20. | <https://doi.org/10.15836/ccar2019.12>

**\*ADDRESS FOR CORRESPONDENCE:** Martina Lovrić Benčić, Klinički bolnički centar Zagreb, Kišpatičeva 12, HR-10000 Zagreb, Croatia. / Phone: +385-91-228-2240 / E-mail: [mlbencic@icloud.com](mailto:mlbencic@icloud.com)

**ORCID:** Juraj Jug, <https://orcid.org/0000-0002-3189-1518> • Martina Lovrić Benčić, <https://orcid.org/0000-0001-8446-6120>

**TO CITE THIS ARTICLE:** Jug J, Lovrić Benčić M. Arrhythmogenic right ventricular cardiomyopathy. *Cardiol Croat.* 2019;14(1-2):12-20. | <https://doi.org/10.15836/ccar2019.12>

**TO LINK TO THIS ARTICLE:** <https://doi.org/10.15836/ccar2019.12>

Aritmogeni kardiomiopatija desne klijetke (ARVC, prethodno zvana „displazija“) rijetka je genska bolest srca koju čine strukturne nepravilnosti miocita desne klijetke

Arrhythmogenic right ventricular cardiomyopathy (ARVC, previously called “dysplasia“) is a rare genetic heart disease caused by structural irregularities in right ventricular (RV)

(DK) te pojava ventrikulskih aritmija. U općoj populaciji prevalencija varira između 1 : 1000 do 1 : 10 000, ovisno o zemljopisnoj regiji.<sup>1-3</sup> Riječ je o progresivnoj zamjeni tkiva miokarda DK-a fibroznom masnim tkivom koje počinje na epikardu te se širi preko sredine miokarda na cijelu stijenku DK-a. Takva progresija može prouzročiti nastanak aneurizmi klijetke te znatne promjene sposobnosti provođenja normalnih impulsa u desnome srcu. Degeneracija tkiva miokarda može se u kasnijim stadijima bolesti proširiti i na lijevu klijetku (LK), iako u vrlo rijetkim slučajevima LK može biti primarno mjesto nastanka bolesti. Određena količina masnoga tkiva miokarda pojavljuje se i u zdravoj DK te se povećava s dobi i tjelesnom masom.<sup>3,4</sup> Ventrikulske aritmije u ovoj bolesti mogu se očitovati kao ekstrasistole (VES), kao bilo koji od oblika ventrikulske tahikardije (VT) te nakraju i fibrilacije ventrikula (VF).<sup>2</sup>

Prirodni tijek ARVC-a uključuje četiri kliničko-patološka stadija: **1.** supklinički stadij, povezan samo s mikroskopskim ultrastrukturnim promjenama miokarda, pri čemu iznenadna srčana smrt (ISS) može biti prvi znak bolesti; **2.** simptomatski stadij, pri kojemu je pojava aritmija morfologije bloka lijeve grane (LBBB) vrlo učestala, kao i brojni simptomi kao što su palpitacije, sinkopa te ISS. Tek u tom stadiju moguće je dokazati bolest slikovnim dijagnostičkim metodama; **3.** progresivna disfunkcija DK-a, često povezana i sa zahvaćanjem i zatajivanjem LK-a; **4.** globalna dilatacija DK-a i biventrikularno proširenje bolesti koje uzrokuje zatajivanje srca.<sup>1,5</sup>

## Etiologija

ARVC je najčešće autosomno-dominantna nasljedna bolest, iako postoje i autosomno-recesivni sindromi povezani s njim. Jedan je od njih je Naxosova bolest u kojoj zbog mutacije gena za plakoglobin nastaje strukturni poremećaj dezmosoma i adherentnih spojeva te se očituje palmoplantarnom keratodermijom i kovrčavom dlakavošću.<sup>2</sup> Najvažnije se autosomno-dominantne mutacije odnose na dezmosome i njihovu funkciju. Danas postoji više od 140 različitih mutacija koje mogu utjecati na razvoj ARVC-a. Najveći se broj pronađenih ultrastrukturnih promjena u ARVC-u odnosi na remodeliranje interkaliranih diskova s pogrešnim smještajem te smanjenim brojem dezmosoma u miokardu DK. Budući da je glavna funkcija dezmosoma održavanje normalne funkcije pukotinskih spojeva, pojavljuju se međustanični problemi u signalizaciji, što u konačnici uzrokuje poremećaj staničnog rasta, diferencijacije, razvoja i normalnog provođenja električnih impulsa.<sup>2,3</sup> Opisani su i slučajevi mutacija više gena u istih osoba pri čemu se kod njih bolest pojavljivala u ranijoj dobi s težim aritmijama. Najbrojnije mutacije svakako se odnose na gene za plakofilin 2 te dezmosoglein 2, oba odgovorna za funkciju dezmosoma.<sup>1,6</sup> Prevalencija mutacija većine gena, osim plakofilina, koji mogu uzrokovati ARVC jednaka je i u muškaraca i u žena, no, fenotipski gledano, bolest je pretežito teža u muškaraca, možda zbog većih volumena i lošije funkcije DK-a.<sup>7</sup> Najveći broj promjena DK-a odnosi se uglavnom na stražnji donji dio ulaznoga trakta desne klijetke (UTDK) po kraj trikuspidnog zalistka i prednji infundibul klijetke, no pronađene su promjene i na apikalnom dijelu DK-a te se ove tri lokalizacije zajedno nazivaju „trokutom displazije“ (slika 1).<sup>2,8</sup> Degeneracija i smrt miocita te njihova zamjena masnim tkivom rezultat su poremećene funkcije dezmosoma kao ključnog čimbenika u održavanju njihove normalne funkcije, što u konačnici uzrokuje upalu te formaciju fibroznog ožiljka koji

myocytes and the presentation of ventricular arrhythmias. The prevalence in the general population varies between 1:1000 to 1:10000 depending on geographical region.<sup>1-3</sup> The disease results in the progressive replacement of myocardial tissue in the RV with fatty fibrous tissue that starts at the epicardium and spreads over the middle of the myocardium to the whole RV wall. Such progression can cause ventricular aneurysms and significant changes to the capacity of transferring normal impulses in the right heart. Degeneration of myocardial tissue can spread to the left ventricle (LV) in later stages of the disease, although in rare cases the LV can be the primary localization. A certain amount of fatty tissue can be found in a healthy RV, increasing with age and body mass.<sup>3,4</sup> Ventricular arrhythmias in this disease can manifest as ventricular extrasystole (VES), any form of ventricular tachycardia (VT), and finally as ventricular fibrillation (VF).<sup>2</sup>

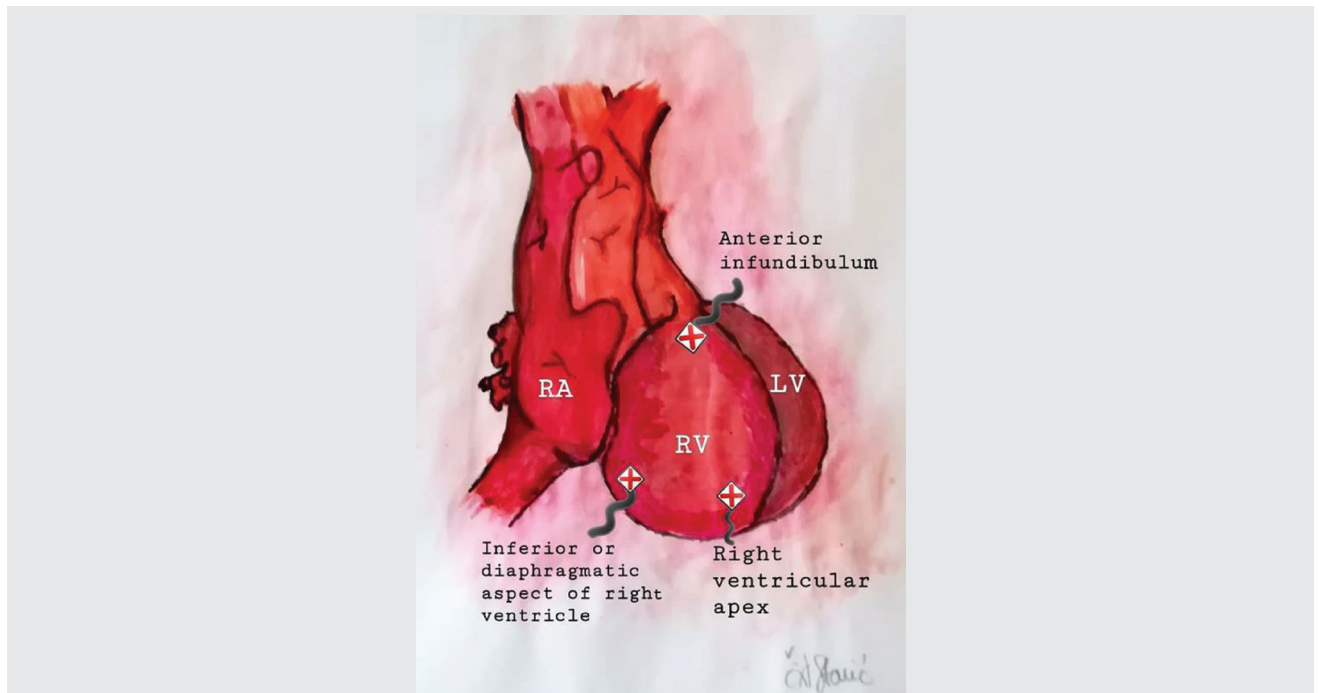
The natural course of ARVC includes four clinicopathological stages. **1.** The subclinical stage, associated with only microscopical ultrastructural changes in the myocardium, where sudden cardiac death can be the first sign of the disease. **2.** The symptomatic stage, in which the manifestation of left bundle branch block (LBBB) morphology arrhythmia is very common, along with numerous other symptoms such as palpitation, syncope, and sudden cardiac death. Only in this stage is it possible to demonstrate the presence of the disease using imaging methods. **3.** Progressive RV dysfunction, often also associated with LV involvement and failure. **4.** Global RV dilatation and biventricular involvement leading to heart failure.<sup>1,5</sup>

## Etiology

ARVC is generally an autosomal dominant hereditary disease, although there are also autosomal recessive syndromes related to it. One of them is Naxos disease, where a mutation of the plakoglobin gene leads to structural disorders of desmosomes and adhesion molecules, which manifest as palmoplantar keratoderma and woolly hair.<sup>2</sup> The most important autosomal dominant mutations are related to desmosomes and their function. Today there are more than 140 different mutations that can influence the development of ARVC. The majority of the ultrastructural changes found in ARVC are related to the remodeling of intercalated discs with incorrect positioning and the reduction of the number of desmosomes in the RV myocardium. Since the main function of desmosomes is maintaining the normal function of gap junctions, intercellular signalization problems occur, eventually leading to disorders in cell growth, differentiation, development, and normal conduction of electrical impulses.<sup>2,3</sup> Cases of multiple gene mutations in the same person have also been described, where the disease manifested at an earlier age with more severe arrhythmias. The largest number of mutations are related to the genes for plakophilin-2 and desmoglein-2, both responsible for desmosome function.<sup>1,6</sup> The prevalence of most gene mutations that can be caused by ARVC is the same in men and women, other than for plakophilin, but from a phenotype perspective the disease severity is predominantly more severe in men, possibly due to larger volumes and poorer RV function.<sup>7</sup> The greatest number of RV changes is mostly related to the lower back part of the RV inflow tract (RVIT) beside the tricuspid valve and forward ventricular infundibulum, but changes have also been found in the apical part of the RV, and these three localizations are jointly called the triangle of dysplasia (Figure 1).<sup>2,8</sup> Degeneration and death of myocytes and their replacement with fatty tissue are

se naknadno zamjenjuje masnim tkivom. Sve su ove promjene posebno bitne pri izrazitom opterećenju DK-a, što se fiziološki pojavljuje tijekom učestale i teške tjelesne aktivnosti.<sup>1,2</sup> Funkcionalno, fokalna stanjenja stijenke slobodnog zida DK-a uzrokuju regionalne kontrakcijske nepravilnosti, sistoličke ili dijastoličke disfunkcije DK-a, pojavu aneurizama klijetke te dilatacije i hipokineze dijela stijenke. Posebno je zanimljivo da je interventrikulski septum uglavnom pošteđen promjena.<sup>5</sup>

the result of disordered desmosome function, as the key factor in the maintenance of myocyte function, which eventually leads to inflammation and formation of a fibrous scar that is subsequently replaced with fatty tissue. All these changes are especially significant with severe RV load that manifests physiologically during repeated strenuous physical activity.<sup>1,2</sup> Functionally, focal thinning of RV free wall results in regional contraction irregularities, systolic and diastolic RV dysfunction.



**FIGURE 1. Triangle of dysplasia, anterior view. Illustration by Ante Čović Stanić.**

RA = right atrium, RV = right ventricle, LV = left ventricle.

### Klinička slika

Simptomi bolesti iznimno se rijetko se pojavljuju prije 12. te nakon 60. godine života. Srednja životna dob pojave simptoma bolesti obično je  $36 \pm 14$  godina, a u muškaraca se očituju 3 puta češće nego u žena. Očituje se s vrlo varijabilnim simptomima, uključujući palpitacije, sinkopu, bol u prsima, zudu te ISS.<sup>4,6</sup> ARVC je vodeći uzrok ISS-a u osoba mlađih od 40 godina. Tri četvrtine epizoda ISS-a događa se tijekom obavljanja rutinskih dnevnih aktivnosti, 10 % tijekom perioperativnog razdoblja, a samo 3,5 % tijekom teške tjelesne aktivnosti.<sup>4</sup>

### Elektrokardiografske promjene

Potpuno normalan nalaz 12-kanalnog elektrokardiograma (EKG) nalazimo u oko 12 % osoba s ARVC-om, no postojanje promjena nalaza EKG-a ne dokazuje postojanje ARVC-a. Odgoda terminalnoga aktivacijskog vremena pojavljuje se u 5 – 20 % slučajeva te se prezentira kao produženje S-vala u odvodima V1 – V3 s najdužom vrijednosti od dna S-vala do kraja cijelog QRS-kompleksa u iznosu većem od 55 ms s izostankom r'. Drugo obilježje jest pojava kompletnog ili in-

tion, ventricular aneurysms, and the dilatation and hypokinesis of a part of the ventricular wall. It is especially interesting that the interventricular septum is mostly spared any changes.<sup>5</sup>

### Clinical presentation

Disease symptoms are extremely rare below age 12 and above age 60. Median age for symptom manifestation is usually  $36 \pm 14$  years of age, with symptoms being 3 times more common in men compared with women. It presents very variable symptoms, including palpitation, syncope, chest pain, dyspnea, and sudden cardiac death (SCD).<sup>4,6</sup> ARVC is the leading cause of SCD in persons younger than 40. Three quarters of SCD episodes take place during routine daily activities, 10% during the perioperative period, and only 3.5% during strenuous physical activity.<sup>4</sup>

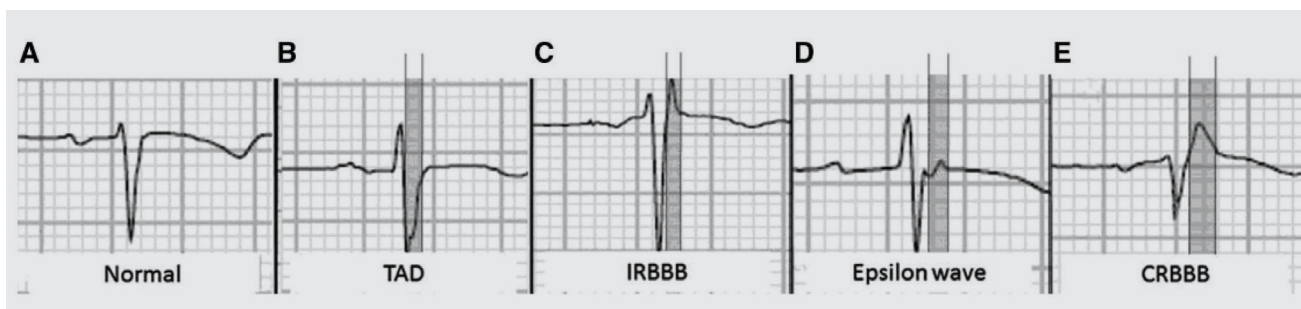
### Echocardiographic changes

A completely normal 12-lead electrocardiogram (ECG) result can be observed in about 12% of persons with ARVC, but changes in the ECG results do not demonstrate the presence of ARVC. Prolonged terminal activation duration is observed in approximately 5-20%



kompletnog bloka desne grane (RBBB) koji pokazuje poremećenu provodljivost Purkinjeovih vlakana. Važno je isključiti ostala stanja koja mogu uzrokovati iste pojavu u EKG nalazu, a njih čine atletsko srce, *pectus excavatum*, i pogrešan položaj postavljenih elektroda za odvođe V1 i V2 na prsnom košu. Opasnija stanja koja mogu dovesti do istih obilježja jesu povećanje DK, preeksitacija LK-a, hiperkalijemija te oblik Brugada tip 2.<sup>9</sup> Relativno specifično obilježje ARVC-a jest pojava epsilon-vala. Nažalost, njegova je pojava zabilježena u samo 10 – 35 % slučajeva ARVC-a. Riječ je o naknadnim ekscitacijskim potencijalima male amplitude pretežito iz slobodne stijenke zida DK-a i izlaznoga trakta desne klijetke (ITDK) koji se pojavljuju unutar ST-segmenta bez elevacije ili depresije u odvodima V1 – V3.<sup>2,9</sup> Četvrta pojava u EKG-u jest regionalna odgoda normalne depolarizacije ventrikula, a prezentira se kao fragmentacija QRS-kompleksa (fQRS) u obliku zareza, usporenja te pojavom  $\geq 4$  šiljaka unutar QRS-kompleksa. Takva pojava se očituje i u brojnim drugim bolestima kao što su Brugadin sindrom i kardiomiopatije. Asimetrični inverzni T-valovi u odvodima V1 i V2 u osoba starijih od 14 godina mogu upućivati na ARVC, a pojavljuju se češće od epsilon-valova. Posebno je bitan vrlo duboki negativni T-val ( $>3\text{mm}$ ) u odvodu V1.<sup>9</sup> Sve su navedene promjene prikazane su na **slici 2**.

of cases and presents as a prolongation of the S wave in V1-V3 leads, with the longest value from the bottom of the S wave to the end of the whole QRS complex in an amount exceeding 55 ms with r' omission. The second characteristic is the appearance of a complete or incomplete right bundle branch block (RBBB) that indicates disordered conductivity of the Purkinje fibers. It is important to eliminate other states that can lead to the same phenomenon in ECG results, which include athletic heart, *pectus excavatum*, and improper positioning of the V1 and V2 lead electrodes on the thorax. More dangerous states that can present with the same characteristics are RV enlargement, LV pre-excitation, hypercalcemia, and Brugada type 2.<sup>9</sup> Presence of the epsilon wave is a characteristic that is relatively specific to ARVC. Unfortunately, it has been found in only 10-35% of ARVC cases. It is caused by subsequent excitatory low-amplitude potentials predominantly from the free RV wall and the outflow tract of the right ventricle (RVOT) which appear within the ST segment without elevation or depression in V1-V3 leads.<sup>2,9</sup> The fourth phenomenon in the ECG is the regional delay of the normal ventricular depolarization, presenting as a fragmentation of the QRS complex (fQRS) in the shape of a comma, deceleration, and the presence of  $\geq 4$  spikes within the QRS complex. Such a phenomenon can also be found in many other diseases such as Brugada syn-



**FIGURE 2. Electrocardiographic morphologies of different conditions seen in lead V1.**

TAD = terminal activation duration, IRBBB = incomplete right bundle branch block, CRBBB = complete right bundle branch block.

Neotkriveni bolesnici s pozitivnom obiteljskom anamnezom ARVC-a imaju veći rizik od razvoja aritmija. Stoga su pronalazak inverzije T-vala u odvodu V1 i V2 nakon 14. godine života te ukupnoga broja  $>1000$  VES / 24 sata ključni za postavljanje dijagnoze u članova takvih obitelji. Zbog ukupne male osjetljivosti i specifičnosti EKG-a kao pretrage za otkrivanje ARVC-a, brojni slučajevi i danas ostaju nedijagnosticirani te se najčešće otkriju evaluacijom nastalih zloćudnih aritmija ili, nažalost, post mortem.<sup>6</sup> Unatoč tomu, VF se rjeđe pojavljuje u starijih bolesnika s dugim trajanjem bolesti, uz pretpostavku da veći udio fibroznoa tkiva pogoduje nastanku hemodinamski stabilne VT.<sup>3</sup>

## Postavljanje dijagnoze

Prvi kriteriji za dijagnozu nastali su 1994. godine pod nazivom *Task Force Criteria* (TFC). Radi poboljšanja osjetljivosti i specifičnosti kriterija 2010. godine napravljena je njihova revizija, no uvjeti za postavljanje dijagnoze ostali su isti. Prema tome, za postavljanje dijagnoze ARVC-a potrebno je zadovoljiti 2 velika kriterija, 1 veliki i 2 mala ili 4 mala kriterija. Revizija iz 2010. godine obuhvaća 6 glavnih kategorija prikazanih u **tablici 1**.<sup>2,10</sup> Slikovne dijagnostičke metode imaju vrlo važnu

drome and cardiomyopathies. Asymmetrical inverted T waves in the V1 and V2 leads in persons above the age of 14 can indicate ARVC, and are more common than epsilon waves. Especially significant is a very deep negative T wave ( $>3\text{mm}$ ) in the V1 lead.<sup>9</sup> All the above mentioned changes are shown in **Figure 2**.

Undiagnosed cases with family history positive for ARVC have a higher risk of developing arrhythmias. Consequently, observing T wave inversion in the V1 and V2 leads after 14 years of age and a total number  $>1000$  VES / 24 hours are key in establishing the diagnosis in the members of such families. Due to low overall sensitivity and specificity of ECG as a test for ARVC, many cases still remain undiagnosed even today, and are usually discovered during the evaluation of malignant arrhythmias or, unfortunately, post-mortem.<sup>6</sup> Despite that, VF is less common in older patients with longer disease duration, under the assumption that a higher ratio of fibrous tissue facilitates the development of hemodynamically stable VT.<sup>3</sup>

## Establishing the diagnosis

The first diagnostic criteria were developed in 1994 under the name *Task Force Criteria* (TFC). They were revised in 2010 to improve their sensitivity and specificity, but the criteria for es-

TABLE 1. Task Force Criteria for diagnosis of arrhythmogenic right ventricular cardiomyopathy<sup>2</sup>.

Category	Major Criteria	Minor Criteria
1. Global or Regional dysfunction and structural abnormalities	Severe dilatation and reduction of RV ejection fraction with no or mild LV involvement. Localized RV aneurysms. Severe segmental dilatation of RV.	Mild global RV dilatation or ejection fraction reduction with normal LV. Mild segmental dilatation of RV. Regional RV hypokinesia.
2. Tissue characteristics of walls	Fibro-fatty replacement of myocardium on biopsy	
3. and 4. ECG abnormalities	Epsilon waves or localized prolongation (<110ms) of QRS complex in right precordial leads	Inverted T waves in V2-V3 leads in subjects > 12 years and in the absence of RBBB
5. Arrhythmias	LBBB-like VT on ECG or Holter monitoring or during exercise testing More than 1000/24h PVC-s on Holter	
6. Family history	Confirmed at necropsy or surgery	Premature sudden death due to suspected ARVC

RV = right ventricle, LV = left ventricle, RBBB = right bundle branch block, LBBB = left bundle branch block, PVC = premature ventricular contraction, ECG = electrocardiogram, VT = ventricular tachycardia, ARVC = arrhythmogenic right ventricular cardiomyopathy.

ulogu u kompletnim TFC kriterijima. Najvažnija od njih jest angiografija DK-a zbog svoje visoke specifičnosti, no ehokardiografija i kardiološka magnetna rezonancija (CMR) danas su tu pretragu gotovo potpuno zamijenile. Unatoč tomu, dijagnoza se još uvijek ne može postaviti na temelju samo jednog nalaza jedne od spomenutih pretraga, nego samo kombinacijom više njih.<sup>1-3</sup> CMR se pokazao odličnim za rano otkrivanje bolesti jer odlično prepoznaje područja regionalne i dijastoličke disfunkcije klijetke, a dodatkom gadolinijevskog kontrasta može prepoznati i područja intramiokardijalne fibroze. Nažalost, u kasnijim stadijima bolesti osjetljivost je CMR-a niža.<sup>3</sup> Biopsiju je poželjno raditi na slobodnoj stijenci DK-a jer bolest uglavnom pošteduje septum DK-a. Pozitivan patohistološki nalaz biopsijom također nije dovoljan za postavljanje konačne dijagnoze, nego je kao veliki kriterij svrstan u TFC kriterije. Vrlo važna pretraga jest i trodimenzionalno elektroanatomsko mapiranje (TEM) koje može otkriti područja niskog napona. Takva područja fibroznim i masnim tkivom mogu odgovarati zamijenjenom miokardu i uvelike pomaže u razlikovanju upalne kardiomiopatije te idiopatske tahikardije iz ITDK-a, bolestima koje mogu imati slično kliničku sliku kao ARVC.<sup>2,3</sup> Promjer se DK-a se, iako nije sadržan u TFC kriterijima, pokazao kao dobar pokazatelj rizika od nastanka aritmija. Istraživanje Lerena i sur.<sup>11</sup> jasno pokazuje izrazito povišen rizik od nastanka aritmija ako je promjer DK-a  $\geq 41$  mm. Također je nehomogena kontrakcija DK, koja se u EKG-u može prikazati kao mehaničko raspršenje potencijala  $\geq 37$  ms, povezana s pojavom teških aritmija ishodišta iz DK-a.

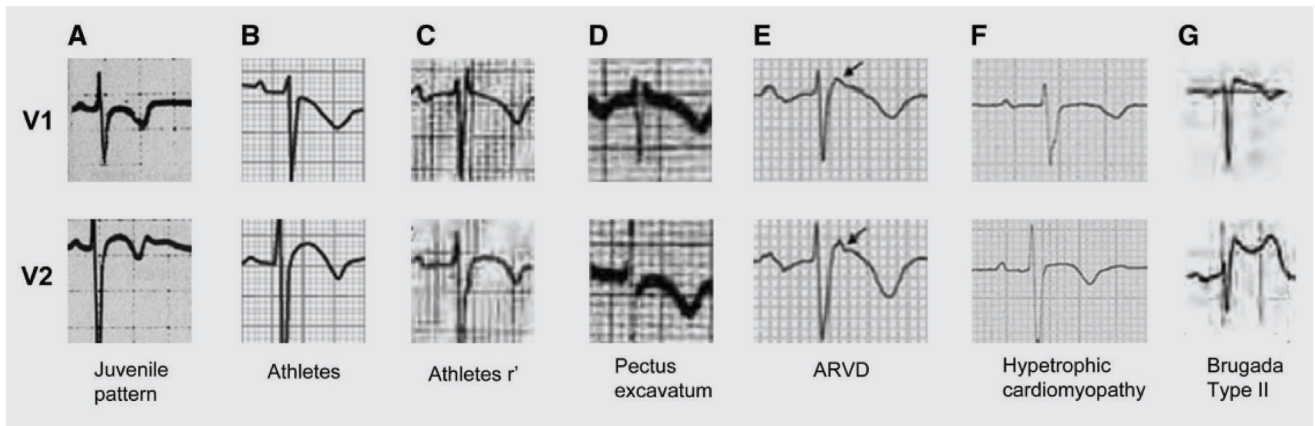
## Diferencijalna dijagnoza

Postoje brojna stanja koja mogu uzrokovati vrlo slične simptome kao ARVC. Idiopatska aritmija ITDK-a svakako je najčešći dijagnostički problem s obzirom na ovu bolest. Usto treba obratiti pozornost i na EKG nalaz sportskog srca koje može prikriti pravu dijagnozu ARVC-a (slika 3. B, C). Svaka VT s lokaliziranim poremećajem pokretljivosti slobodne stijenke klijetke s upalom ili bez nje može biti uzrokovana sarkoidozom srca ili miokarditisom. Razlikovanje navedenih bolesti može omogućiti samo patohistološka potvrda, odnosno nalaz

tablišting the diagnosis remained the same. Accordingly, establishing the diagnosis of ARVC requires the fulfillment of 2 major criteria, 1 major and 2 minor criteria, or 4 minor criteria. The revision from 2010 encompasses 6 main categories shown in **Table 1**.<sup>2,10</sup> Imaging methods have a very important role in the TFC criteria. The most important of them is RV angiography due to its high specificity, but echocardiography and cardiac magnetic resonance (CMR) have now almost completely replaced it. Nevertheless, the diagnosis still cannot be established on the basis of one finding from one of these tests, but only with a combination of them.<sup>1-3</sup> CMR has also proven to be excellent for early disease detection because it is excellent in recognizing areas of regional and diastolic ventricular dysfunction, and with the addition of a gadolinium contrast medium it can also recognize areas of intramyocardial fibrosis. Unfortunately, the sensitivity of CMR in later stages of the disease is lower.<sup>3</sup> Biopsies should be performed on the RV free wall, since the disease usually spares the RV septum. Positive pathohistological biopsy findings are also not sufficient to establish the final diagnosis, but are instead classified as a major criterion in the TFC. Three-dimensional electroanatomical mapping (TEM) is also an important test that can reveal areas of low voltage areas. Such areas can represent the replacement of myocardial tissues with fibrous and fatty tissues, and the test is very helpful in differentiating inflammatory cardiomyopathy and idiopathic tachycardia from the RVIT, which are diseases that can have a similar clinical picture as ARVC.<sup>2,3</sup> The RV diameter, although not present in the TFC, has shown itself to be a good risk indicator for the development of arrhythmias. A study by Leren et al.<sup>11</sup> clearly showed significantly increased risk of arrhythmia if the RV diameter is  $\geq 41$  mm. Furthermore, non-homogenous RV contraction, which can appear on the ECG as a mechanical potential dispersion of  $\geq 37$  ms, is associated with the appearance of severe arrhythmias originating in the RV.

## Differential diagnosis

There are numerous states that can cause very similar symptoms as ARVC. Idiopathic RVOT arrhythmia is definitely the most common diagnostic problem regarding this disease. At-



**FIGURE 3. Conditions with benign patterns of negative T wave in leads V1–V2.**

ARVD = arrhythmogenic right ventricular dysplasia.

biopsije srca. Manje specifičan nalaz u sarkoidozi jest pojava bolesti provodnog sustava pri kojoj dolazi do produženja PR-intervalu i AV-bloka, što gotovo nikada ne nastaje u ARVC-u. Budući da se i u kasnijim stadijima ARVC-a mogu vidjeti QRS-kompleksi niskog naponu, u procjeni miokarditisa najveću ulogu ima obiteljska anamneza. Ako je ona negativna, povećava se vjerojatnost da je posrijedi miokarditis.<sup>4</sup>

Vrlo rijedak poremećaj DK-a jest i Uhl-ova anomalija karakterizirana nedostatkom miokarda DK-a s apozicijom endokarda i epikarda. Druga urođena anomalija jest i prethodno spomenut *pectus excavatum* koji zbog svojih anatomskih obilježja mijenja EKG nalaz osobe (slika 3., D).<sup>3,4</sup>

Razlikovanje ARVC-a od dilatativne kardiomiopatije koja zahvaća DK može biti vrlo teško ako je riječ o kasnijim stadijima bolesti s ejekcijskom frakcijom lijeve klijetke < 50 %. Ipak VT i ISS iznimno su rijetki u dilatativnoj kardiomiopatiji te se njihovom pojavom povećava vjerojatnost da je posrijedi ARVC-u. Premda rijetko, Brugada sindrom koji sadržava promjene tipa 2 u EKG-u može se dijagnosticirati umjesto ARVC-a (slika 3., G). Tipična elevacija ST-segmenta u obliku tipa 1 Brugada sindroma gotovo se nikada ne viđa u ARVC-u. Treba navesti još i hipertrofičnu kardiomiopatiju kao rijedak, ali važan problem u diferencijalnoj dijagnozi ARVC-a (slika 3., F).<sup>4</sup> Unatoč svim dijagnostičkim metodama i algoritmima, više od 50 % pravih ARVC-a i danas ostaje pogrešno dijagnosticirano.<sup>2,4,9</sup>

### Utjecaj tjelesne aktivnosti na razvoj bolesti

Posebna se pozornost pridaje ARVC-u u sportu. Kirchof *i sur.*<sup>12</sup> na transgeničnim plakoglobin deficijntnim miševima pokazali su da su aktivnosti koje zahtijevaju veliku izdržljivost povezane s povećanjem DK-a, usporenjem provođenja u DK-u te pojavom povećanog broja aritmija ishodišta slobodne stijenke DK-a. Također, Fabritz *i sur.*<sup>13</sup> naknadno su dokazali da poštuda takvih miševa sprječava razvoj fenotipa ARVC-a. Ni u jednom od ovih istraživanja nisu pronađeni dokazi fibroznih ili masnih promjena miokarda miševa. James *i sur.*<sup>14</sup> prvi su na ljudima dokazali utjecaj tjelesne aktivnosti na progresiju ARVC-a. Istraživanje pruža vrlo važna otkrića za shvaćanje naravi ARVC-a. Najvažnija su: 1. simptomatska faza bolesti pojavljuje se vrlo rano u životu veoma aktivnih

pažnja treba biti posvećena i rezultatima EKG-a za sportsko srce, što može zamaskirati pravi dijagnozu ARVC (slika 3., B, C). Svaki VT s lokaliziranim poremećajem mobilnosti zida slobodne stijenke s ili bez upalnih promjena može biti uzrokovan srčanim sarkoidozom ili miokarditisom. Diferencijacija ovih bolesti moguća je samo s potvrdom patohistološkom, tj. rezultatima srčane biopsije. Manje specifičan nalaz u sarkoidozi jest prisutnost bolesti provodnog sustava s produženjem PR-intervalu i AV-blokom, što gotovo nikada ne nastaje u ARVC-u. Budući da se i u kasnijim stadijima ARVC-a mogu vidjeti QRS-kompleksi niskog naponu, u procjeni miokarditisa najveću ulogu ima obiteljska anamneza. Ako je ona negativna, povećava se vjerojatnost da je posrijedi miokarditis.<sup>4</sup>

Uhl-ova anomalija je vrlo rijedak poremećaj DK-a karakteriziran nedostatkom miokarda DK-a s apozicijom endokarda i epikarda. Druga urođena anomalija jest i prethodno spomenut *pectus excavatum* koji zbog svojih anatomskih obilježja mijenja EKG nalaz osobe (slika 3., D).<sup>3,4</sup>

Diferencijacija ARVC-a od dilatativne kardiomiopatije koja zahvaća DK može biti vrlo teško ako je riječ o kasnijim stadijima bolesti s ejekcijskom frakcijom lijeve klijetke < 50 %, ali ipak VT i ISS iznimno su rijetki u dilatativnoj kardiomiopatiji te se njihovom pojavom povećava vjerojatnost da je posrijedi ARVC-u. Premda rijetko, Brugada sindrom koji sadržava promjene tipa 2 u EKG-u može se dijagnosticirati umjesto ARVC-a (slika 3., G). Tipična elevacija ST-segmenta u obliku tipa 1 Brugada sindroma gotovo se nikada ne viđa u ARVC-u. Treba navesti još i hipertrofičnu kardiomiopatiju kao rijedak, ali važan problem u diferencijalnoj dijagnozi ARVC-a (slika 3., F).<sup>4</sup> Unatoč svim dijagnostičkim metodama i algoritmima, više od 50 % pravih ARVC-a i danas ostaje pogrešno dijagnosticirano.<sup>2,4,9</sup>

### The influence of physical activity on arrhythmogenic right ventricular cardiomyopathy

U sportu, ARVC-u se pridaje posebna pozornost. Kirchof *et al.*<sup>12</sup> used transgenic plakoglobin-deficient mice to demonstrate that activities requiring great endurance are associated with RV enlargement, slowed conduction to the RV, and the appearance of an increased number of arrhythmias of RV free wall origin. Fabritz *et al.*<sup>13</sup> later demonstrated that sparing in such



sportaša nositelja gena za razvoj ARVC-a te se usto pojavljuje i lošiji nalaz na CMR-u, **2.** dužina i vrsta aktivnosti uvjetuju vrijeme razvoja ARVC-a, **3.** dugogodišnji aktivni sportaši imaju mnogo lošiju prognozu i ishod ventrikulskih aritmija, **4.** dugogodišnji aktivni sportaši koji se nakon dijagnoze ARVC-a nastave baviti sportom imaju lošije preživljenje u usporedbi s onima koji su se nakon postavljanja dijagnoze prestali baviti istim sportom.

Iznimno važno otkriće, koje podupire prethodno navedene teorije, jest dokaz da se komponente interkaliranog diska (uključujući i desmosome) počinju povezivati tek oko 1. godine života, a njihovo sazrijevanje i premještanje traje sve do puberteta. Prema tome, prekomjerna količina teške tjelesne aktivnosti od samo 4 sata tjedno u djetinjstvu može znatno modificirati strukturu DK-a, posebno nositelja mutacija koje su mogući uzrok ARVC-a. Takva se pojava tumači smanjenom popustljivošću plućne cirkulacije koja u teškoj tjelesnoj aktivnosti, posredovana povećanim ejekcijskim volumenom DK-a, uzrokuje izrazito povišenje tlaka u plućnoj cirkulaciji. Ako se opterećenje DK-a u takvom slučaju uspoređi s onim u mirovanju, zaključuje se da je ono veće za 170 %. U takvih osoba ponavljajućim oštećenjem miokarda u nekim slučajevima može nastati zamjena miocita fibroznim ili masnim tkivom te naposljetku životno ugrožavajuće aritmije. Iznimno rijetko, no ipak je moguća pojava ovakvih promjena čak i u vrlo dobro utreniranih sportaša bez pozitivne obiteljske anamneze i pronađene mutacije, koje uzrokuju ARVC.<sup>1</sup> Asimptomatskim sportašima s pozitivnom obiteljskom anamnezom savjetuje se detaljno i učestalo praćenje zdravstvenog stanja već od rane životne dobi. Takvim je osobama zabranjeno sudjelovanje u teškim tjelesnim aktivnostima duže od nekoliko mjeseci zaredom, a potpuno im je zabranjeno ako se pojave znakovi bolesti te se savjetuje treniranje sportova koji iziskuju mali napor.<sup>1,4</sup>

### Liječenje

Odluka o početku liječenja aritmija ishodišta iz DK-a, od kojih su kudikamo najčešće VES, donosi se na temelju simptoma aritmija te postojanja disfunkcije LK-a. U pravilu, ako se uz VES ne nalazi ishemijska miokarda ili prateća strukturna bolest srca, VES se smatraju benignim stanjem. Nalaz više od 20 % VES u 24-satnom holteru EKG-a povezuje se s dugoročnom dilatacijom i disfunkcijom LK-a uz moguću kardiomiopatiju te se preporučuje radiofrekventna ablacija (RF) žarišta takve simptomatske aritmije. Drugi mogući pristup jest konzervativno liječenje čija je glavna svrha smanjenje simptoma uzrokovanih aritmijama uz oprez oko utjecaja lijekova na funkciju sinuatrijskoga čvora, atrioventrikulskog čvora, dužinu QT-intervalu te funkciju jetre i bubrega.<sup>15</sup> Poseban oprez i pristup zahtijeva liječenje ARVC-a te Brugada sindroma jer je njihov tijek nepovoljniji od idiopatskih aritmija ishodišta iz DK-a.

### Medikamentno liječenje

Glavni cilj liječenja ove bolesti jest prevencija ISS-a. Slijedom toga, edukacija bolesnika s ARVC-om neizmerno je važna te se provodi u svrhu ograničenja tjelesne aktivnosti te promjene načina života.<sup>8</sup> Bolesnici s ARVC-om koji su mladi, a nisu imali sinkope, zastoj srca, negativni T-val u prekordijalnim odvodima, isključujući odvod V1, VT te >20 % VES u 24-satnom holteru EKG-a obično nemaju visok rizik od razvoja malignih

mice prevents the development of the ARVC phenotype. None of these studies found evidence of fibrous or fatty myocardial changes in the mice. James et al.<sup>14</sup> were the first to demonstrate the influence of physical activity on ARVC progression in humans. The study presents very significant discoveries for understanding the nature of ARVC. The most important of these are: **1.** The symptomatic phase of the disease takes place very early in the lives of very active athletes who are gene carriers for ARVC, coupled with poorer CMR findings; **2.** The duration and type of activity determines ARVC development time; **3.** Longtime active athletes who have been active for many years have a much poorer prognosis and outcomes for ventricular arrhythmias; **4.** Longtime athletes who continue engaging in sports after ARVC diagnosis have poorer survival compared with those who stopped engaging in the same sport after the diagnosis was established.

An extremely important discovery corroborating the theories above is the evidence showing that components of the intercalated disc (including desmosomes) start connecting only around 1 year of age, and their maturation and movement continue until puberty. Accordingly, excessive amounts of strenuous physical activity of only 4 hours per week in childhood can significantly modify the structure of the RV, especially in carriers of mutations that are possible causes of ARVC. This phenomenon is explained by reduced permeability in the pulmonary circulation that, mediated by increased RV ejection fraction in strenuous physical activity, causes extremely elevated pressure in pulmonary circulation. In such cases, RV load can be 170% larger compared with RV load at rest. In such persons, repeated damage to the myocardium can in some cases lead to the replacement of myocytes with fibrous or fatty tissue and eventually the development of potentially lethal arrhythmia. Although it is extremely rare, is it possible for these changes to take place even in well-trained athletes with no positive family history or findings of mutations that cause ARVC.<sup>1</sup> For asymptomatic athletes with positive family history, detailed and frequent monitoring of their state of health from an early age is recommended. Such persons are forbidden to participate in strenuous physical activities more than several months at a time and forbidden to participate at all if signs of the disease appear; choosing a non-strenuous sport is recommended.<sup>1,4</sup>

### Treatment

The decision to start the treatment of arrhythmias originating in the RV, of which VES are the most common, is made based on the symptoms of the arrhythmia and whether or not there is LV dysfunction. As a rule, if VES is not coupled with myocardial ischemia or concomitant structural heart disease, VES is considered a benign state. A finding of more than 20% of VES during 24-hour Holter monitoring is associated with long-term LV dilation and dysfunction with possible cardiomyopathy, so radiofrequency ablation (RFA) of the foci of the symptomatic arrhythmia is recommended. Another possible approach is conservative treatment, where the main goal is to reduce the symptoms caused by arrhythmias while monitoring the influence of medication on the function of the sinoatrial node, atrioventricular node, QT-interval duration, and liver and kidney function.<sup>15</sup> Special caution and a careful approach is warranted by the treatment of ARVC and Brugada syndrome, since their course is less favorable than idiopathic arrhythmias originating in the RV.

aritmija te ne zahtijevaju specifično liječenje antiaritmikima. U ostalih, u svrhu prevencije nastanka malignih aritmija te ISS-a najučinkovitijim se pokazao sotalol (68 % učinkovitosti). Ipak, pojedina istraživanja navode kako beta-blokatori nemaju ni zaštitnički ni štetni učinak u liječenju ARVC-a dovodeći tako amiodaron na prvo mjesto po učinkovitosti.<sup>2,5</sup> Ostali lijekovi koji se mogu rabiti u liječenju ove bolesti, sami ili u kombinacijama s prethodno navedenima, jesu antiaritmici I. a skupine (prokainamid), I. b (meksiletin) te I. c skupine (flecainid i propafenon) s vrlo promjenjivim uspjehom.<sup>8</sup>

### **Prevencija iznenadne srčane smrti ugradnjom kardioverterskog defibrilatora**

Automatski ugradbeni kardioverterski defibrilator (ICD) uređaj je koji pravodobno registrira pojavu maligne aritmije te je u tom trenutku defibrilira. U bolesnika s ARVC-om te Brugada sindromom u određenoj fazi prirodnog tijeka bolesti postoji visoki rizik od razvoja malignih aritmija. Važno je naglasiti kako je za ugradnju ICD-a ključno individualno odrediti koliki je taj rizik te je li ICD u tog bolesnika doista potreban.<sup>8</sup>

Uzimajući u obzir da svaka pojava malignih aritmija može završiti smrću, istraživanje koje su proveli Corrado *i sur.*<sup>16</sup> dokazuje da je stvarno preživljenje bolesnika s ARVC-om te ugrađenim ICD-om iznosilo 99 % u 12-mjesečnom, 98 % u 24-mjesečnom te 96 % u 36-mjesečnom praćenju. U usporedbi s tim, u bolesnika bez ugrađenog ICD-a preživljenje u istim tim intervalima praćenja iznosilo bi 88 %, 79 % te 72 %, što izravno dokazuje da ICD od ISS-a spašava 23 % bolesnika. Usprkos tomu, profilaktična ugradnja ICD-a u asimptomatskih bolesnika ili u osoba prenositelja gena za ARVC za sada nije preporučljiva zbog toga što ukupna količina komplikacija nastalih nakon ugradnje premašuje stvarnu korist od funkcije ICD-a.<sup>3</sup> Ukupni broj komplikacija nakon ugradnje ICD-a u bolesnika s ARVC-om veći je nego u ostalih bolesti koje su indikacija za njegovu ugradnju.<sup>2</sup>

### **Ablacija aritmija ishodišta iz izlaznoga trakta desne klijetke**

Glavna apsolutna indikacija za izvedbu ablacije ITDK-a jest pojava učestalih aritmija sa simptomima u pacijenata sa strukturnom bolešću srca ili bez simptoma. Ostale indikacije uključuju slab odgovor aritmija na medikamentnu terapiju te odluku bolesnika o načinu liječenja.<sup>15</sup>

RF ablacija ovog ishodišta učinkovito smanjuje broj VES-a u 24-satnom holteru EKG-a, znatno smanjuje ili uklanja sve simptome aritmije, poboljšava kvalitetu života, popravljajući stanje kardiomiopatije te ejekcijsku frakciju LK-a.<sup>15</sup>

Uspješnost RF ablacije u ARVC-u mnogo je manja zbog pojave novih žarišta uzrokovanih fibroznim i/ili masnim promjenama miokarda koji svojim histološkim obilježjima omogućuju nastanak aritmija mehanizmom kruženja. Aritmije takvih ishodišta pokazuju različite QRS-komplekse te su nađene u 40 – 60 % bolesnika s ARVC-om u višegodišnjem praćenju nakon ablacije.<sup>2,5,17,18</sup> U skladu s tim, ablacija aritmogenih žarišta DK-a u ARVC-u palijativna je metoda liječenja i dugoročno ne smanjuje rizik od ISS-a.<sup>6</sup>

### **Transplantacija srca**

Kongestivno zatajivanje srca nastalo širenjem fibroznoga masnog tkiva na LK u progresiji ARVC-a moguće je izliječiti samo ortotopičnom transplantacijom srca. Transplantacija se kao opcija liječenja mora uzeti u obzir u bolesnika s refrak-

### **Medication treatment**

The main goal of the treatment of this disease is the prevention of SCD. Consequently, educating patients with ARVC is of paramount importance and is performed with the goal of limiting physical activity and changing the patient's lifestyle.<sup>8</sup> Patients with ARVC who are young and did not present with syncope, heart failure, negative T wave in the precordial leads excluding the V1 lead, VT, and >20% VES during 24-hour Holter monitoring usually do not have a high risk for the development of malignant arrhythmias and do not require specific treatment with antiarrhythmic drugs. In others, prevention of the development of malignant arrhythmias and SCD is most effectively achieved by sotalol (68% effectiveness). However, individual studies indicate that beta-blockers have neither a protective nor a harmful effect in the treatment of ARVC, making amiodarone the most effective medication.<sup>2,5</sup> Other medications that can be used for the treatment of this disease, either singly or in combination with those listed above, are antiarrhythmic drugs of the Ia class (procainamide), Ib class (mexiletine), and the Ic class (flecainide and propafenone) that have been used with varying success.<sup>8</sup>

### **Prevention of sudden cardiac death with an implantable cardioverter defibrillator**

An implantable cardioverter defibrillator (ICD) is a device that registers the appearance of malignant arrhythmia and defibrillates it in a timely manner. In patients with ARVC and Brugada syndrome there is a high risk for development of malignant arrhythmias in a certain phase of the natural course of the disease. It is important to emphasize that individually ascertaining that risk and whether an ICD is really necessary in a given patient is a crucial aspect of ICD application.<sup>8</sup>

Bearing in mind that every manifestation of malignant arrhythmia can end in death, a study by Corrado *et al.*<sup>16</sup> demonstrated that the real survival of patients with ARVC using an ICD was 99% in 12-month follow-up, 98% in 24-month follow-up, and 96% in 36-month follow-up. In comparison, patient survival in these follow-up intervals with no ICD would be 88%, 79%, and 72%, respectively, which directly demonstrates that ICD saves 23% of patients from SCD. Despite this, however, prophylactic use of ICDs in asymptomatic patients or persons carrying the ARVC gene is currently not recommended because the total amount of complications after ICD implantation is greater than the real benefits of the ICD.<sup>3</sup> The total number of complications after ICD implantation in patients with ARVC is higher than in other diseases for which ICDs are indicated.<sup>2</sup>

### **Ablation for arrhythmias originating in the right ventricular outflow tract**

The main absolute indication for RVOT ablation is the presence of frequent arrhythmias with or without symptoms in patients with structural heart disease. Other indications include poor response to medication treatment and patient choice.<sup>15</sup>

RF ablation of this focus effectively reduces the VES number in 24 hour Holter monitoring, significantly reduces or eliminates all symptoms of arrhythmia, improves quality of life, and improves cardiomyopathy status and LV ejection fraction.<sup>15</sup>

The successfulness of RF ablation in ARVC is significantly lower due to the appearance of new foci caused by fibrous and/or fatty tissue changes in the myocardium, whose histological characteristics permit circus-like re-entry arrhythmias. Arrhythmias with such foci present different QRS complexes and



tornim srčanog zatajivanjem s nekontroliranim aritmijama ili bez njih.<sup>5,19</sup>

have been observed in 40-60% of patients with ARVC during long-term follow-up after ablation.<sup>2,5,17,18</sup> Ablation of arrhythmogenic RV foci in ARVC is therefore only a palliative treatment method and does not reduce the risk of SCD in the long term.<sup>6</sup>

### Heart transplantation

Congestive heart failure caused by expansion of fibrous fatty tissue to the LV in the progression of ARVC can be cured only by orthotropic heart transplantation. Transplantation must be considered as a treatment option in case of refractory heart failure with or without uncontrolled arrhythmias.<sup>5,19</sup>

### LITERATURE

1. Sawant AC, Calkins H. Relationship Between Arrhythmogenic Right Ventricular Dysplasia and Exercise. *Card Electrophysiol Clin*. 2015 Jun;7(2):195-206. <https://doi.org/10.1016/j.ccep.2015.03.004>
2. Capulzini L, Brugada P, Brugada J, Brugada R. Arrhythmia and right heart disease: from genetic basis to clinical practice. *Rev Esp Cardiol*. 2010 Aug;63(8):963-83. [https://doi.org/10.1016/S0300-8932\(10\)70208-6](https://doi.org/10.1016/S0300-8932(10)70208-6)
3. Basso C, Corrado D, Marcus FI, Nava A, Thiene G. Arrhythmogenic right ventricular cardiomyopathy. *Lancet*. 2009 Apr 11;373(9671):1289-300. [https://doi.org/10.1016/S0140-6736\(09\)60256-7](https://doi.org/10.1016/S0140-6736(09)60256-7)
4. Sen-Chowdhry S, Lowe MD, Sporton SC, McKenna WJ. Arrhythmogenic right ventricular cardiomyopathy: Clinical presentation, diagnosis, and management. *Am J Med*. 2004 Nov 1;117(9):685-95. <https://doi.org/10.1016/j.amjmed.2004.04.028>
5. Thiene G, Corrado D, Basso C. Arrhythmogenic right ventricular cardiomyopathy/dysplasia. *Orphanet J Rare Dis*. 2007;2(1):45. <https://doi.org/10.1186/1750-1172-2-45>
6. Calkins H, Corrado D, Marcus F. Risk Stratification in arrhythmogenic right ventricular cardiomyopathy. *Circulation*. 2017 Nov 21;136(21):2068-2082. <https://doi.org/10.1161/CIRCULATIONAHA.117.030792>
7. Bauce B, Frigo G, Marcus FI, Basso C, Rampazzo A, Maddalena F, et al. Comparison of clinical features of arrhythmogenic right ventricular cardiomyopathy in men versus women. *Am J Cardiol*. 2008 Nov 1;102(9):1252-1257. <https://doi.org/10.1016/j.amjcard.2008.06.054>
8. Anderson EL. Arrhythmogenic right ventricular dysplasia. *Am Fam Physician*. 2006 Mar;73(8). <https://doi.org/10.1016/j.cpcardiol.2012.12.002>
9. Nunes de Alencar Neto J, Baranchuk A, Bayes Genis A. Arrhythmogenic right ventricular dysplasia/cardiomyopathy: an electrocardiogram-based review. *Europace*. 2018 Jun 1;20 F1:f3-12. <https://doi.org/10.1093/europace/eux202>
10. Marcus FI, McKenna WJ, Sherrill D, Basso C, Bauce B, Blumke DA, et al. Diagnosis of arrhythmogenic right ventricular cardiomyopathy/Dysplasia: Proposed modification of the task force criteria. *Circulation*. 2010 Feb 19;121(13):1533-1541. <https://doi.org/10.1161/CIRCULATIONAHA.108.840827>
11. Leren IS, Saberniak J, Haland TF, Evarsdn T, Haugaa KH. Combination of ECG and echocardiography for identification of arrhythmic event sin early ARVC. *JACC Cardiovasc Imaging*. 2017 May;10(5):503-513. <https://doi.org/10.1016/j.jcmg.2016.06.011>
12. Kirchhof P, Fabritz L, Zwiener M, Witt H, Schäfers M, Zellerhoff S, et al. Age and training development of arrhythmogenic right ventricular cardiomyopathy in heterozygous plakoglobin-deficient mice. *Circulation*. 2006 Oct 9;114(17):1799-1806. <https://doi.org/10.1161/CIRCULATIONAHA.106.624502>
13. Fabritz L, Hoogendijk MG, Scicluna BP, van Amersfoort SC, Fortmueller L, Wolf S, et al. Load-reducing therapy prevents development of arrhythmogenic right ventricular cardiomyopathy in plakoglobin-deficient mice. *J Am Coll Cardiol*. 2011 Feb 8;57(6):740-750. <https://doi.org/10.1016/j.jacc.2010.09.046>
14. James CA, Bhonsale A, Tichnell C, Murray B, Russell SD, Tandri H, et al. Exercise increases age-related penetrance and arrhythmic risk in arrhythmogenic right ventricular dysplasia/cardiomyopathy-associated desmosomal mutation carriers. *J Am Coll Cardiol*. 2013 Oct 1;62(14):1290-1297. <https://doi.org/10.1016/j.jacc.2013.06.033>
15. Eugenio PL. Frequent premature ventricular contractions: An electrical link to cardiomyopathy. *Cardiol Rev*. 2015 Jul;23(4):168-172. <https://doi.org/10.1097/CRD.000000000000063>
16. Corrado D, Leoni L, Link MS, Della Bella P, Gaita F, Curnis A, et al. Implantable cardioverter-defibrillator therapy for prevention of sudden death in patients with arrhythmogenic right ventricular cardiomyopathy/dysplasia. *Circulation*. 2003 Nov 24;108(25):3084-3091. <https://doi.org/10.1161/01.CIR.0000103130.33451.D2>
17. Issa ZF, Miller JM, Zipes DP. Adenosine-sensitive (outflow tract) ventricular tachycardia. *Clin Arrhythmology electrophysiol a companion to Braunwald's heart disease*. 2012;567:562-586. <https://doi.org/10.1016/b978-1-4557-1274-8.00023-3>
18. Niroomand F, Carbucicchio C, Tondo C, Riva S, Fassini G, Apostolo A, et al. Electrophysiological characteristics and outcome in patients with idiopathic right ventricular arrhythmia compared with arrhythmogenic right ventricular dysplasia. *Heart*. 2002 Jan 1;87(1):41-47. <https://doi.org/10.1136/heart.87.1.41>
19. Fiorelli AI, Coelho GH, Oliveira JL Jr, Nascimento CN, Vilas Boas LB, Napolitano CF, et al. Heart transplantation in arrhythmogenic right ventricular dysplasia: Case reports. *Transplant Proc*. 2009 Apr 1;41(3):962-964. <https://doi.org/10.1016/j.transproceed.2009.02.010>